

fizjoterapia polska



POLISH JOURNAL OF PHYSIOTHERAPY

OFICJALNE PISMO POLSKIEGO TOWARZYSTWA FIZJOTERAPII

THE OFFICIAL JOURNAL OF THE POLISH SOCIETY OF PHYSIOTHERAPY

NR 2/2023 (23) KWARTALNIK ISSN 1642-0136

**Przebieg zachorowania na COVID-19
w odniesieniu do zmysłu węchu,
smaku i wzroku**

The SARS-CoV-2 virus
contributes to disorders of the
sense of smell, taste and vision
by attacking many important
structures in human body

Znaczenie systematycznej rehabilitacji na przestrzeni 45 lat pacjentki z rozwojową dysplazją stawu biodrowego
The importance of systematic rehabilitation over 45 yrs of a patient with developmental dysplasia of the hip joint

ZAMÓW PRENUMERATE!

SUBSCRIBE!

www.fizjoterapiapolska.pl

www.djstudio.shop.pl

prenumerata@fizjoterapiapolska.pl





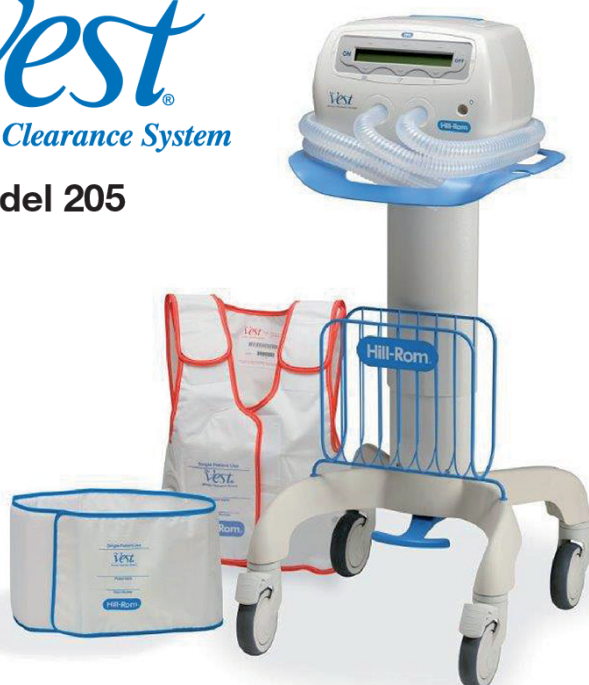MATIO sp. z o.o.

to sprawdzony od 7 lat dystrybutor
urządzeń do drenażu dróg oddechowych
amerykańskiej firmy Hillrom

Hill-Rom.

The
Vest
Airway Clearance System


model 205



MetaNeb™



**sprzęt medyczny do drenażu i nebulizacji dla pacjentów w warunkach szpitalnych
– ze sprzętu w Polsce korzysta wiele oddziałów rehabilitacji i OIOM**



Rok założenia firmy 1996
www.butterfly-mag.com
tel. 85 743 22 21
kom. 603 299 035



BIOMAGNETOTERAPIA W WYROBACH MEDYCZNYCH „ORT BUTTERFLY”

- BEZ BÓLU, STRESU I BEZ TABLETEK!
- LECZYSZ SIĘ NATURALNIE
- ŚPIĄC, PRACUJĄC, WYPOCZYWAJĄC...
- USUWASZ BÓL I JEGO PRZYCZYNĘ!
- TERAPIA STARA JAK ŚWIAT!
- SPRAWDZA SIĘ I DAJE RADĘ W NIERÓWNEJ WALCE Z PANDEMIĄ – COVID 19!

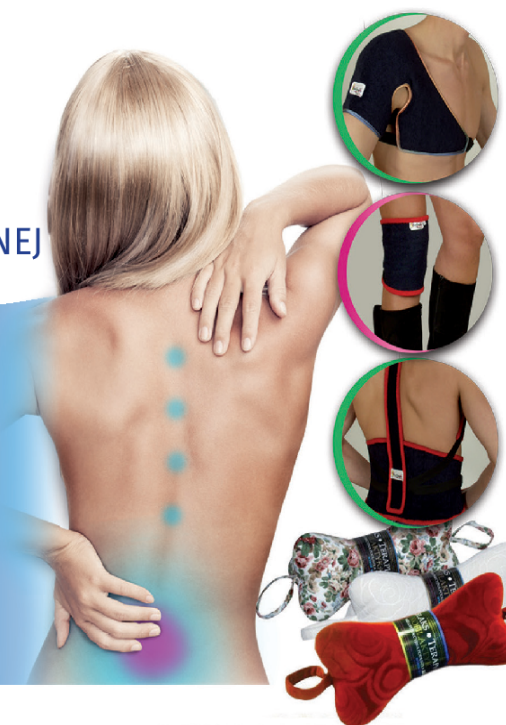REGULARNA BIOSTYMULACJA MAGNETYCZNA!

Ogromny potencjał Natury w zwalczaniu smogu energetycznego i autooksydacji, będącej główną przyczyną wszystkich chorób cywilizacyjnych!

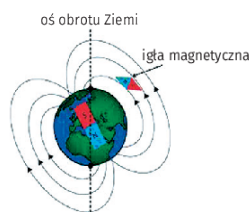
Najstarsza Terapia Świata wspomagająca każdą formę leczenia!

Uważa się do dziś, że bez niej nie da się wyleczyć żadnej choroby do końca!

Naturalna Terapia Magnetyczna Twoje Zdrowie, Twoja Uroda, Odporność i Sprawność do późnej starości! **Wypróbuj** – gdy zawiodły już inne terapie!



Biomagnetoterapia inicjuje ożywienie komórkowe, oczyszcza i „odmładza” krew, podnosząc vitalność całego organizmu, który uruchamia intuicyjne procesy obronne, znosząc dyskomfort powodowany bólem, urazem lub stresem, bez konieczności ostrej dawki leków chemicznych...



DLACZEGO CHORUJEMY?

Natężenie sztucznych pól elektromagnetycznych zwiększyło się 100 tys. razy! Naturalne pole magnetyczne Ziemi zmniejszyło swą moc o połowę!



BIOMAGNETYZM - jako antidotum; jedyne i absolutne; na cancerogenną ekspansję „smogu energetycznego”!

ZŁOTE LOGO
Międzynarodowych Targów
Rehabilitacja
Łódź IX/2007



Jestem osobistym królikiem doświadczalnym! I żyję – realizując 25 lat wciąż nowe i śmielsze pomysły w wykorzystaniu tej **boskiej energii** naturalnych magnesów! Dzięki nim pokonuję dziś niezliczone przeszkody i przeciwności losu z nieznaną mi przedtem energią i determinacją! To moja pasja! I przeznaczenie!

Najnowsza opinia klienta:

Komentarz ten jest moim osobistym świadectwem zadowolenia z produktów biomagnetycznych „Ort Butterfly”, których używam od 20. lat! Zastanawiam się, zwłaszcza nad fenomenem poduszki (określenie nie jest przypadkowe) zwyczajnie; nie wyobrażam sobie snu i wypoczynku bez magnetycznej „Ort Butterfly” – pod głowę! Jej ergonomiczny, przyjazny dla głowy i szyi kształt sprawia, że wysypiam się „po królewsku”. Zabieram ją również ze sobą w bliższe i dalsze podróże! Czyż gdyby była to zwyczajna poduszka, fundowałbym sobie dodatkowy bagaż? Wychwalam więc ją od zarania, polecam i rekomenduję, bo jest tego warta! Bez niej nie wyobrażam sobie prawdziwie relaksacyjnego snu i błogiego, kojącego wypoczynku! Dziękuję, że ją Pani stworzyła!

J. Szew. Działdowo (maj 2020)

PS Poduszki „Ort Butterfly” to prawdziwe arcydziełka robione z wyczuciem i sercem... jak rzeźby Michała Anioła... Polecam wszystkim!

3 Kongres Rehabilitacja Polska

Perspektywy rozwoju Fizjoterapii

Organizator



Polskie Towarzystwo
Fizjoterapii

Współorganizator



Polskie Towarzystwo
Rehabilitacji

8-9 grudnia 2023
Hotel Fabryka Wełny w Pabianicach
strona internetowa: ptf-3kongres.pl

Termin	do 20.08.2023	do 30.10.2023	po 1.11.2023
Student	200	300	550
Członek PTF	300	400	550
Niezmieszony	400	500	550
Student grupowo (od 10 os)	-	150	200
Lunch 1 dzień	80	110	120
Lunch 2 dni	150	200	210
Bankiet	350	400	450

Streszczenia prac należy przysyłać wyłącznie za pomocą formularza znajdującego się na stronie ptf-3kongres.pl (gdzie znajduje się wykaz tematów oraz wymagania dotyczące plakatów).

Patroni

fizjoterapia
polska

Acta Balneologica
Journal of the Polish Balneology and Physical Association

XVII JESIENNE DNI FIZJOTERAPII

Fizjoterapia w praktyce

Janów Lubelski. 29 września – 1 października 2023



POLSKIE TOWARZYSTWO FIZJOTERAPII

ODDZIAŁY

LUBELSKI, PODKARPACKI, MAZOWIECKI



Kolegium Nauk Medycznych Uniwersytetu Rzeszowskiego



Wydział Rehabilitacji – Akademii Wychowania Fizycznego w Warszawie

Prosimy o przesłanie streszczeń referatów na adres: konferencjajdf@gmail.com do dnia 30 czerwca 2023 r. Organizatorzy przewidują sesję studencką i sesję plakatową.

Opłata konferencyjna obejmuje: uczestnictwo w konferencji, materiały, obiad, przerwy kawowe, warsztaty.

Dodatkowo płatne: ognisko integracyjne w piątek 29 września – 80 zł oraz bankiet w sobotę 30 września – 150 zł.

Uczestnicy	Opłata do 31 lipca 2023	Opłata po 31 lipca 2023
Członkowie: PTF, PSSF, OZZPF	200 zł	240 zł
Studenci	100 zł	140 zł
Pozostałe osoby	250 zł	340 zł

Zgłoszenie uczestnictwa prosimy dokonywać poprzez wpłatę na konto Oddziału Podkarpackiego PTF:

29 9162 0000 2001 0014 1413 0001

oraz przesłanie na pocztę konferencjajdf@gmail.com imienia, nazwiska i miejsca zamieszkania każdego z uczestników konferencji, tytuł naukowy, adres e-mail, nr telefonu, z jakiego oddziału PTF/PSSF/OZZPF lub niezrzeszony, dane do faktury, potwierdzenie dokonania wpłaty za konferencję, ognisko integracyjne oraz bankiet.

Dodatkowe informacje: Sławomir Jandziś 504068500



fizjoterapia polska

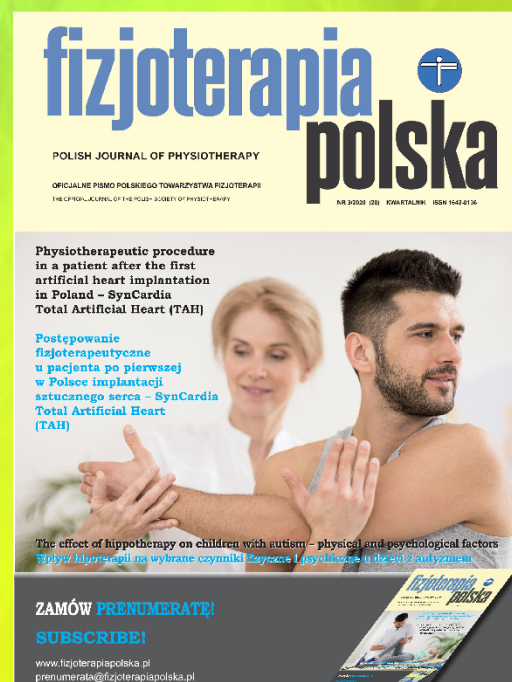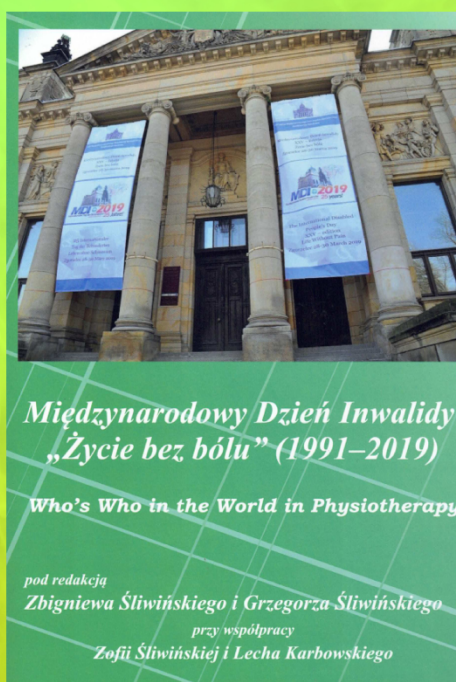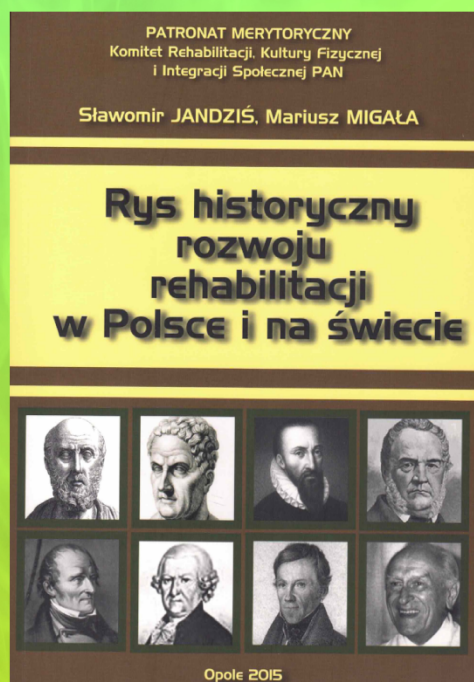


STUDIO

sklep internetowy:
www.djstudio.shop.pl

w sklepie dostępne między innymi:

- *archiwalne numery Fizjoterapii Polskiej w wersji papierowej*
- *artykuły w wersji elektronicznej*
- *książki poświęcone fizjoterapii*
- *prenumerata Fizjoterapii Polskiej*



An interdisciplinary concept for the treatment of Bell's palsy – a case report

Interdyscyplinarna koncepcja leczenia porażenia Bella – opis przypadku

**Konrad Kijak^{1(A,B)}, Łukasz Kopacz^{2(A,B)}, Grzegorz Cieślak^{3(A,E)}, Zbigniew Śliwiński^{4(E,F)},
Piotr Skomro^{2(E,F)}, Małgorzata Kowacka^{5(B,E)}, Paweł Berczyński^{6(B,F)}, Danuta Lietz-Kijak^{2(E,G)}**

¹Student Scientific Society at the Department of Internal Medicine, Angiology and Physical Medicine, Medical University of Silesia in Katowice, Poland

²Department of Propaedeutic, Physical Diagnostics and Dental Physiotherapy, Pomeranian Medical University in Szczecin, Poland

³Department of Internal Medicine, Angiology and Physical Medicine, Medical University of Silesia in Katowice, Poland

⁴Department of Physiotherapy, Collegium Medicum UJK in Kielce, Poland

⁵Independent Public Health Care Complex in Żarki, Poland

⁶Private Dental Practice Maciej Górski, Szczecin, Poland

Abstract

Background. Bell's palsy is a spontaneous paralysis of the facial nerve (i.e. cranial nerve VII). It presents with muscle weakness leading to facial asymmetry, with a drooping corner of the mouth, loss of the ability to whistle, blink, close the eyelid, purse lips or grin. The forehead on the affected side becomes smooth and the patient is not able to frown or raise eyebrows.

Objective. The aim of the study was to evaluate the effect of combined electrophysical and physiotherapeutic methods on accelerating recovery from facial nerve palsy.

Material and Methods. The authors describe two cases of Bell's palsy, treated with simultaneous application of electrophysical agents, in the form of an extremely low-frequency electromagnetic field (ELF-EMF) and high-energy LED light, and physiotherapy modalities, i.e. proprioceptive neuromuscular facilitation (PNF) and kinesiotaping (KT).

Results. After four weeks of electrophysical and physiotherapeutic treatments, a fully satisfactory and stable therapeutic effect was achieved.

Conclusions. The interdisciplinary therapy using ELF-EMF + LED combined with PNF and KT treatments proved to be effective in accelerating recovery from facial nerve palsy. Further studies are needed to establish appropriate protocols.

Keywords

Bell's palsy, electrophysical agents, physiotherapy, LED light therapy with extremely low frequency electromagnetic field (ELF-MF), proprioceptive neuromuscular facilitation (PNF), kinesiotaping (KT).

Streszczenie

Wprowadzenie. Porażenie Bella to samoistne porażenie nerwu twarzowego (czyli nerwu czaszkowego VII). Objawia się osłabieniem mięśni prowadzącym do asymetrii twarzy, opadającym kącikiem ust, utratą zdolności gwizdania, mrugania, zamykania powiek, zaciskania ust czy uśmiechania się. Czoło po stronie dotkniętej chorobą staje się gładkie, a pacjent nie jest w stanie marszczyć ani unosić brwi.

Cel. Celem badania była ocena wpływu łączonych metod elektrofizycznych i fizjoterapeutycznych na przyspieszenie powrotu do zdrowia po porażeniu nerwu twarzowego.

Materiał i metody. Autorzy opisują dwa przypadki porażenia Bella, leczonego z jednoczesnym zastosowaniem metod elektrofizycznych w postaci pola elektromagnetycznego o skrajnie niskiej częstotliwości (ELF-EMF) i wysokoenergetycznego światła LED oraz metod fizjoterapii, tj. proprioceptywnego nerwowo-mięśniowego torowania ruchu (PNF) i kinesiotapingu (KT).

Wyniki. Po czterech tygodniach zabiegów elektrofizycznych i fizjoterapeutycznych uzyskano w pełni zadowalający i stabilny efekt terapeutyczny.

Wnioski. Terapia interdyscyplinarna z wykorzystaniem ELF-EMF + LED w połączeniu z zabiegami PNF i KT okazała się skuteczna w przyspieszeniu powrotu do zdrowia po porażeniu nerwu twarzowego. Konieczne są dalsze badania w celu ustalenia odpowiednich protokołów.

Słowa kluczowe

porażenie Bella, metody elektrofizyczne, fizjoterapia, terapia światłem LED i polem elektromagnetycznym o ekstremalnie niskiej częstotliwości (ELF-MF), proprioceptywne nerwowo-mięśniowe torowanie ruchu (PNF), kinesiotaping (KT)

Introduction

Bell's palsy is a spontaneous paralysis of the facial nerve (i.e. cranial nerve VII). The paralysis presents with muscle weakness leading to facial asymmetry, with a drooping corner of the mouth, loss of the ability to whistle, blink, close the eyelid, frown, raise eyebrows, purse lips or grin. In addition, food can become trapped in the vestibule of the cheek, deep sensation in the facial area is impaired, as is tear production. Apart from unilateral facial muscle weakness, patients may report dry eye and dry mouth, altered taste and increased sensitivity to food intake. The patient's face is asymmetrical, the forehead on the affected side becomes smooth and the patient is not able to frown or raise eyebrows. Due to paralysis of the oculomotor muscle, the eye may appear wider than on the healthy side, the patient may not be able to close the eyelid and the corneal reflex is absent [1].

The pathogenesis of Bell's palsy is unknown, although a viral aetiology of the condition is suspected [1, 2]. It is believed that unilateral facial muscle weakness may result from facial nerve inflammation and swelling caused by the reactivation of the herpes simplex or herpes zoster virus [1–3]. Pregnancy, severe preeclampsia, obesity, hypertension, diabetes and respiratory diseases such as upper respiratory tract infections of viral origin have been implicated as specific risk factors for Bell's palsy. Bell's palsy is diagnosed by eliminating other disease entities that may be causing the symptoms [1–3]. During the diagnostic process, a comprehensive history and physical examination aim to exclude neurological, otorhinolaryngological, infectious and inflammatory or neoplastic factors, as well as cerebellopontine angle pathology or vascular insufficiency. The House-Brackmann grading system is useful for evaluating changes in nerve function [4–6].

The estimated incidence of Bell's palsy is 10–40 per 100,000 people. Spontaneous resolution can be observed, with approximately 71% of patients experiencing clinical improvement within three weeks of the onset of the first symptoms and complete recovery within three months. The remainder of patients do not make a full recovery and continue to complain of facial weakness and contractures [7]. Facial dysfunction has a significant impact on the patient's appearance, psychological wellbeing and quality of life [8]. In this condition, it is advisable to start medication as soon as possible to relieve swelling and improve circulation. Pharmacological treatment must be accompanied by rehabilitation, including physical treatments and neuromuscular therapy (NMT) [2]. The therapeutic management of Bell's palsy aims to achieve full recovery or, in cases where there is no chance of full recovery, to reduce the negative consequences. The primary treatment approach in confirmed cases of this disease entity is pharmacotherapy, in the form of corticosteroids, which should be started within 72 hours of the onset of symptoms. Antiviral treatment in combination with corticosteroid therapy may offer some additional benefit and can be implemented on the basis of shared decision-making by the treatment team when a viral infection is suspected and later confirmed. Apart from medication, treatment for Bell's palsy includes NMT and electrophysical modalities and, in more severe cases, surgery [7]. In the literature, acupuncture and kinesiotaping, in

conjunction with physical therapy modalities, have been reported as safe and promising complementary therapies for the acute management of Bell's palsy [9]. It has also been shown that facial taping combined with Kabat rehabilitation facilitated the reduction of recovery time and improved the outcomes of Bell's palsy [10, 11]. It has also demonstrated that the adequate use of laser-photobiomodulation can be an effective therapeutic option for patients with Bell's palsy, regardless of the age, shortening the recovery time obtained with conventional therapies and avoiding sequelae [12].

There are currently no clear recommendations for the use of acupuncture, electrotherapy or surgical decompression, as there are insufficient reports from well-designed trials and the available data are inadequate [13]. In view of this, the authors planned an interdisciplinary approach using several therapies simultaneously. The aim of the clinical trials presented below was to evaluate the effect of combined electrophysical and physiotherapeutic methods on accelerating recovery from facial nerve palsy.

Material and Methods

Ethics and dissemination: The research team from the Department of Propaedeutic, Physical Diagnostics and Dental Physiotherapy of the Pomeranian Medical University in Szczecin, Poland, who carried out the novel interdisciplinary therapy, obtained approval from the Bio-ethics Committee with the number KB-0012/32/13. The patients described herein gave consent for their faces to be used in the photographs, one of the patients being a dentist and at the same time a co-author of the manuscript.

Patient 1

The patient, aged 27, presented to the Dental Physiotherapy Outpatient Clinic with left-sided facial nerve palsy, 10 days after the first symptoms appeared. The patient's face was asymmetrical, the forehead on the affected side was smooth and he was not able to frown or raise eyebrows. Due to paralysis of the oculomotor muscle, the eye appeared wider than on the healthy side, the patient was not able to close the eyelid completely and the corneal reflex was absent. The buccinator muscle did not produce any facial movements, the nasolabial fold on the affected side was flat and the corner of the mouth drooped. The lips appeared narrower on the affected side, and when attempting to smile or grin, the mouth remained motionless and the patient dragged his lips towards the healthy side.

His history included a tick bite that had occurred one month earlier, and the tick was removed 4 hours after it had penetrated the skin. One week later the patient developed flu-like symptoms, which resolved after symptomatic treatment with antipyretics. Two weeks after the bite, the patient was admitted to the Department of Infectious Diseases with severe headache and positive meningitis symptoms, and remained in hospital for 15 days. No erythema was present at the bite site. Lyme disease was excluded by ELISA and Western blot tests, and viral tick-borne encephalomyelitis was diagnosed, as indicated by high titres of IgM antibodies. The analysis of cerebrospinal fluid (CSF) revealed an elevated level of albumin, but with no specific antibodies for Lyme disease. The day after his discharge from

hospital, the patient had another outpatient neurological consultation, during which Bell's syndrome was diagnosed. In medical history, the patient reported difficulty in chewing food, accumulation of food in the left vestibule, taste disturbance on the left side of the tongue, pain upon compression of the left supraglottic muscles and attachments of the sternocleidomastoid muscle. The patient also noted severe weakness of the shoulder

girdle muscles and transient hand tremor. In addition, he reported constant fatigue and generalised weakness, sleep problems and occasional tinnitus located in the left ear. Physical examination revealed significant weakness, up to grade IV on the House-Brackmann scale, marked asymmetry in mimetic muscle movements with preserved symmetry and tone at rest, and impaired superficial sensation of the face (Fig.1, 2).




Fig. 1. Marked asymmetry of mimetic muscles when producing facial expressions

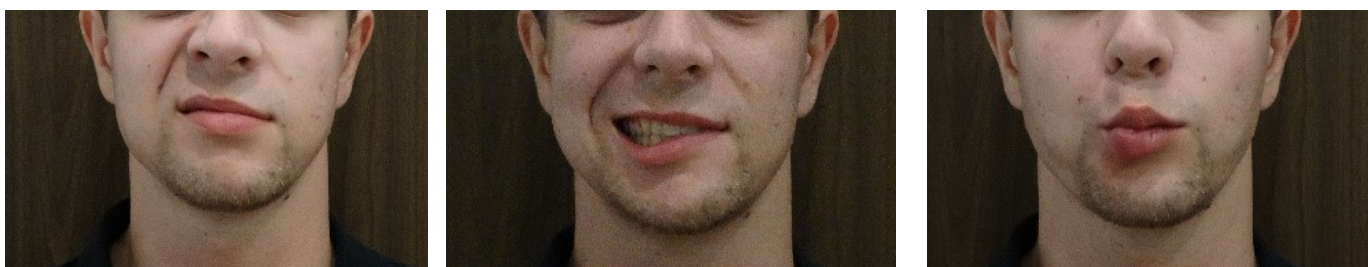


Fig.2. Marked asymmetry of mimetic muscles when producing facial expressions

Patient 2

The second case is a 38-year-old male who presented to the Dental Physiotherapy Outpatient Clinic with facial nerve palsy of the left side, manifested by muscle weakness and impaired mimetic function on that side (Fig.3,4). Prior to his visit at the Clinic, the patient had been hospitalised at the Department of Neurology, where he had a CT scan of the brain and clinical tests which ruled out Lyme disease and otorhinolaryngological pathology. The patient's history included chronic sinusitis, hypercholesterolaemia and a persistent cough that had been present for 3 weeks before the onset of paralysis. The patient was treated with ster-oids and underwent rehabilitation using the methods described below.

One month later, an idiopathic paralysis with similar symptoms occurred on the right side, additionally accompanied by a taste

disorder on the right side of the tongue (Fig.5,6). The patient presented to the Department of Neurology, where this time he had a brain MRI scan, showing discrete contrast enhancement in the peripheral cranial nerve VII (at the fundus of the internal auditory canal) on the right side, and to a lesser degree on the left side, which may potentially point to bilateral Bell's palsy. In addition, a small venous haemangioma was visible in the left frontal lobe; no other lesions were found. On neurological examination, meningeal symptoms were negative, and the features of facial nerve injury on the right side were classified as House-Brackman grade II. These symptoms and the results of the diagnostic tests led to the diagnosis of idiopathic recurrent and alternating Bell's palsy. Corticosteroid therapy and facial mimetic rehabilitation were continued. During the rehabilitation process, the patient took Encorton, Mesopral, Kalipoz and Neurovit.

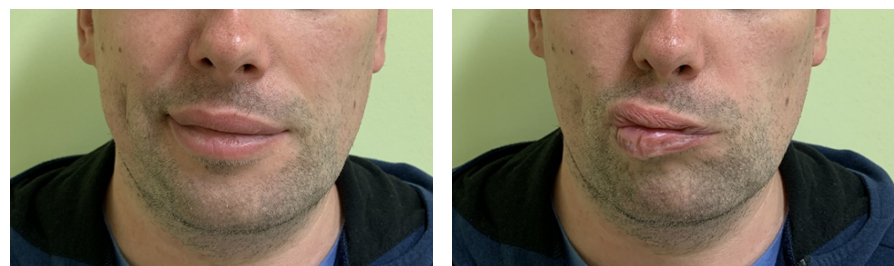

Fig.3. Marked asymmetry of mimetic muscles on the left side when producing facial expressions

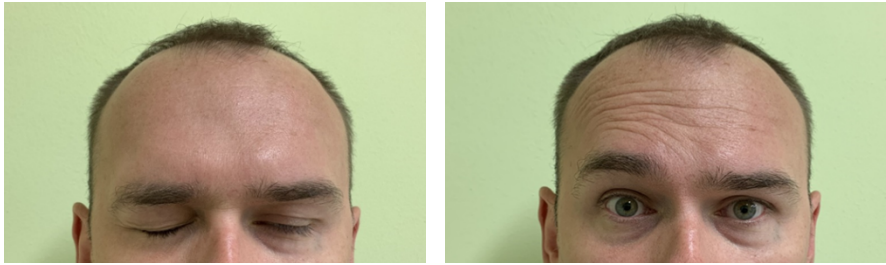

Fig. 4. Marked asymmetry of mimetic muscles on the left side when producing facial expressions

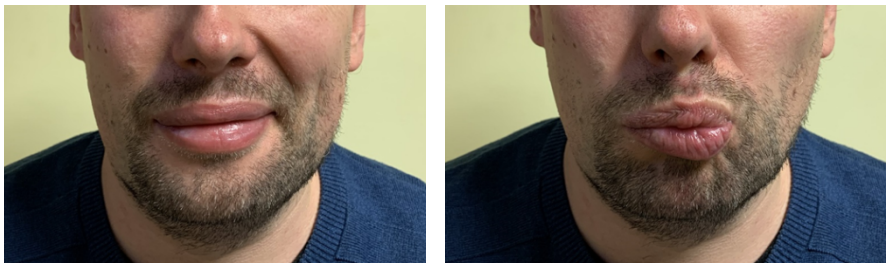

Fig. 5. Marked asymmetry of mimetic muscles on the right side when producing facial expressions

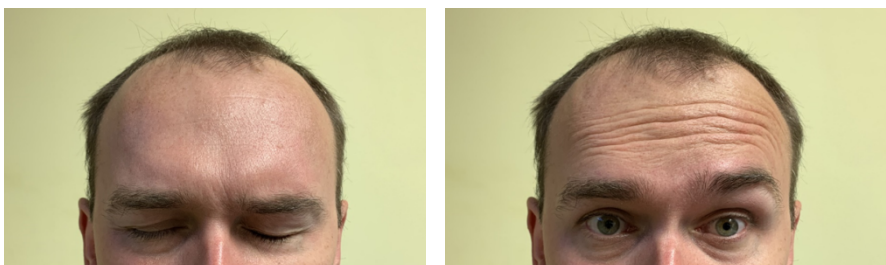

Fig. 6. Marked asymmetry of mimetic muscles on the right side when producing facial expressions

Therapeutic methods

The electrophysical modality used was magnetic field LED therapy, which is the combined application of a slowly changing electromagnetic field of extremely low frequency (Extremely Low Frequency Magnetic Field, ELF-EMF) and light from high-energy LEDs (Light Emitting Diodes) in wavelength ranges corresponding to red (R), infrared (IR) and mixed (RIR) light radiation. Red light is emitted at 630 nm and infrared at 855 nm, the electromagnetic field induction in the VIOFOR JPS System (Med&Life) is 15 μ T with a magnetic field frequency in the range of 180–195 Hz [14]. These electrophysical agents were applied in sessions of 20 minutes every day for four weeks with the use of light-emitting panels, each containing 240 LEDs, half of which emit red light, and the other half infrared light (Fig. 7). The physiotherapeutic modalities employed in the patients' rehabilitation process included proprioceptive neuromuscular facilitation (PNF), leveraging the stretch reflex in facial muscle exercises and applying resistance to activate the muscles and increase their strength. Bilateral movements were used throughout the therapy, so that both sides of the face were exercised at the same time, resulting in greater facial symmetry. The patients' treatment

regimen also included rhythmic initiation, repetition, and combinations of isotonic contraction and relaxation techniques (Fig. 8). After each exercise was presented, the patients repeated it on his own, without manual contact from the physiotherapist. The patients performed exercises in front of a mirror providing essential feedback for both the therapist and the patient [15]. Another part of the treatment regimen was kinesiотaping (KT), with tapes applied to the temporomandibular joint area and the paralysed part of the face (Fig. 9). The main benefits of the KT method include: effects on skeletal muscle function (normalised muscle tone), improved microcirculation, enhanced lymphatic drainage, stimulation of endogenous analgesic mechanisms (pain relief). As a complementary soft tissue therapy method, normalising myofascial tone, KT is an excellent tool in the hands of the physiotherapist for physiotherapeutic treatment and prevention. The effects of KT are primarily sensory, but also proprioceptive. By applying the tapes, the skin surface is gently lifted, increasing the space between it and the fascia. This improves the microcirculation of blood and lymph and activates natural self-healing processes. KT was used to maintain the effects of the therapy and to stimulate structures not controlled by the dysfunctional muscles [16, 17].



Fig. 7. Physical therapy using ELF-EMF combined with high-energy LEDs

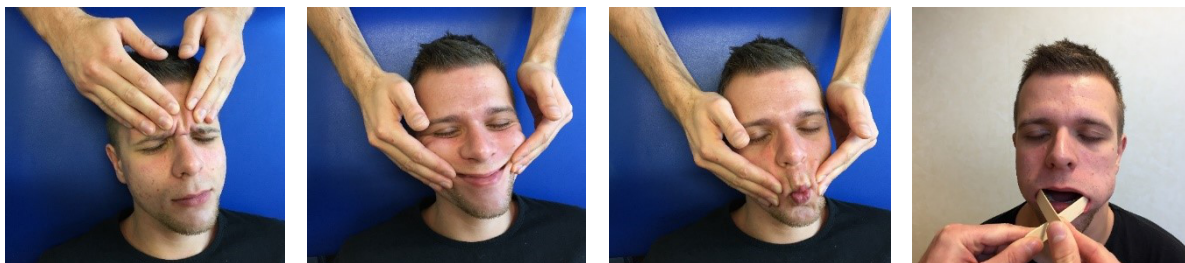


Fig. 8. PNF (proprioceptive neuromuscular facilitation) used in the patient's rehabilitation process

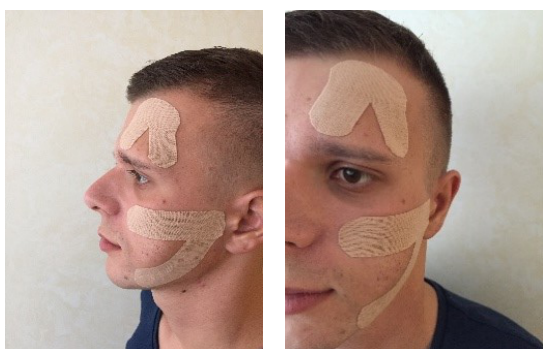

Fig. 9. KT applied to the temporomandibular joint area and the paralysed part of the face

Results

After four weeks of electrophysical therapy in the form of ELF-EMF with LED light, and physiotherapy using PNF and KT modalities, a fully satisfactory therapeutic outcome was

achieved. Patients were able to symmetrically frown, raise their eyebrows, smile and purse their lips to whistle without any difficulty (Fig. 10–14).

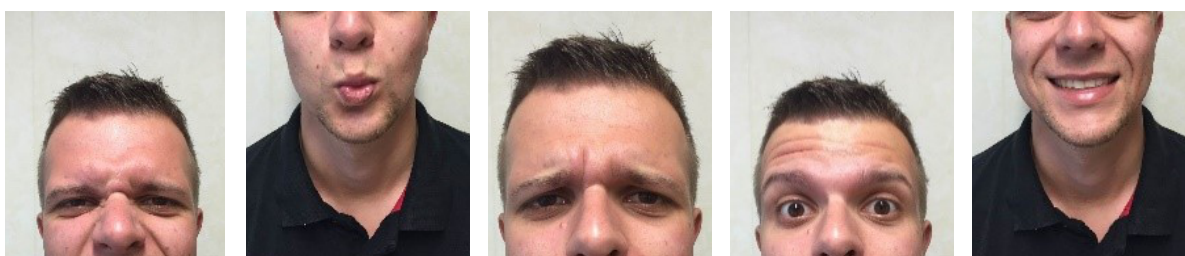


Fig. 10. Visible improvement in mimetic muscle symmetry when producing facial expressions

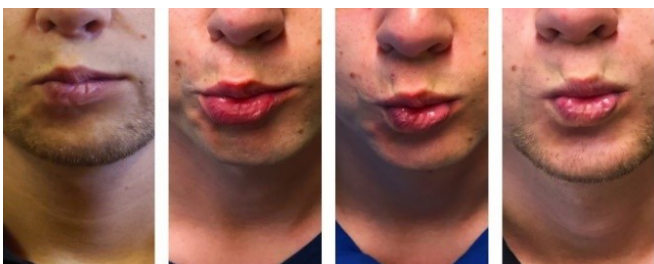

Fig. 11. Progress in facial nerve rehabilitation over four consecutive weeks as illustrated by oral circular muscle function

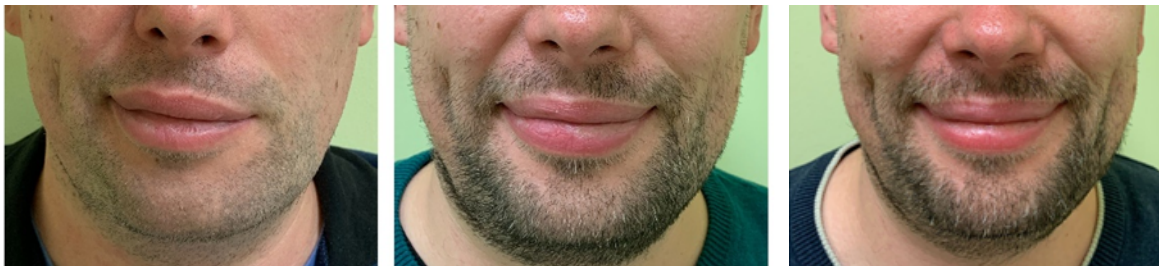

Fig. 12. Effects achieved in rehabilitation in terms of levator anguli oris muscle function on the left side

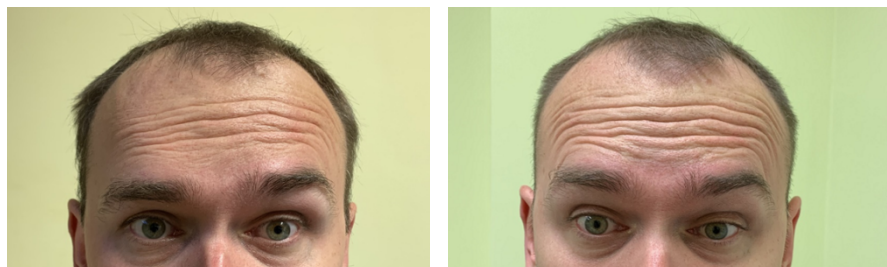

Fig. 13. Effects achieved in rehabilitation in terms of frontalis muscle function on the right side

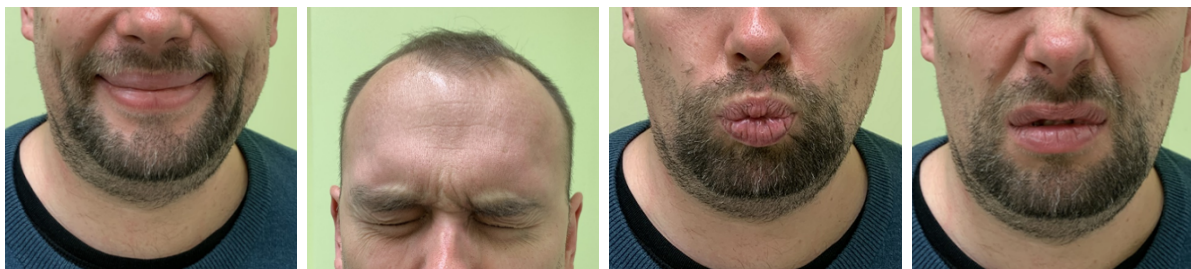

Fig. 14. Visible improvement in mimetic muscle symmetry when producing facial expressions at the end of the full course of

Discussion

The interdisciplinary, innovative and effective therapeutic method presented here using the example of two patients with Bell's palsy was developed by the Department of Pro-paedeutic, Physical Diagnostics and Dental Physiotherapy of the Pomeranian Medical University in Szczecin, Poland. The application of electrophysical modalities, in the form of ELF-EMF + LED light therapy, has been reported to produce the expected therapeutic effect in sensory disorders following surgical procedures or orthognathic surgery [18]. Unfortunately, such spectacular results were not observed in cases of facial or trigeminal nerve palsy. Only when additionally combined with PNF and KT was it possible to achieve a rapid therapeutic effect. It should be noted that the first symptoms of facial nerve restitution may be expected to appear within 6 to 8 weeks, but in more severe cases, full recovery may take several months and the facial muscle function may not be restored, leaving a significant degree of permanent paralysis. Treatment guidelines for Bell's palsy do not recommend the use of physiotherapy due to a lack of good quality trials and inconsistencies in the research to date [2]. No standardised methods or protocols have been identified in this respect. Facial deformity can cause a significant deterioration in the psychological wellbeing of patients, affecting their social relationships, and there is a strong fear of permanent damage to the facial nerve, which translates into a high level of commitment to treatment on the part of the patient [19]. Therefore, in the present study, we sought to determine the

benefits of electrophysical modalities, which are not yet fully understood. It is recognised that patients can benefit psychologically from engaging in exercise therapy.

In the above report, we demonstrate that simultaneous interdisciplinary electrophysical and physiotherapy treatments resulted in complete facial nerve rehabilitation over a four-week treatment period. The analgesic and anti-inflammatory effects of ELF-EMF are widely documented. Thomas et al. used low-frequency electromagnetic fields to treat chronic musculo-skeletal pain and proved their analgesic effect [20]. Arneja et al., in turn, used electromagnetic fields in the treatment of chronic lower back pain in patients with degenerative disc disease. Their pilot study suggests that the EMF treatment protocol has clinical relevance and can be used safely and effectively [21]. Pall concluded that the direct effect of extremely low frequency electromagnetic fields can be attributed to phenomena brought about by the activation of calcium channels and membrane transport processes, as well as increased enzyme activity [22]. In clinical trials involving the elderly with the use of a pulsed electromagnetic field, Iannitti et al. reported significant benefits in the form of reduced joint pain and stiffness, as well as improved physical performance [23]. Nelson et al., in turn, found that non-invasive electromagnetic field therapy resulted in a rapid and significant reduction in pain in the early stages of knee osteoarthritis [24].

Combination electrophysical therapy, ELF-EMF + LED, used in this study, is an innovative method that combines light energy

emitted by high-energy diodes with electromagnetic fields of low frequency and low flux density (induction). No reports were found in the literature on the application of this interdisciplinary method for the rehabilitation of Bell's palsy. The authors have the right to assume that their research is the first to use this electrophysical modality in neuroregeneration. The therapeutic LED light is monochromatic, meaning that it is made up of photons that all have the same wavelength, and it is also collimated, which means that the rays are parallel and do not spread out. However, LED light is not coherent, as not all the photons are in phase with each other, which distinguishes it from laser light [25]. Calderhead et al. confirmed that light energy from LEDs, used chiefly in aesthetic medicine, depending on the wavelength and angle of application, exerts effects on tissues mainly locally with deep penetration capabilities [26]. Barolet, on the other hand, reviewed applications of light energy in dermatology, taking advantage of tissue responses dependent on energy absorption in individual layers. The effects of infrared light (IR), at 830 nm, are initiated at the cell membrane level, while those of red light (R), at 640 nm, in the mitochondria [27]. Simpson found that near-infrared LEDs achieve the deepest tissue penetration of visible wavelengths and are therefore used in therapies targeted at subcutaneous structures and fibroblasts [28]. Red LEDs have been studied in a wide range of applications, including wound healing, treatment of pre-cancerous conditions and warts, and the prevention of oral mucositis. IR LED treatment can penetrate the skin between 5 and 10 mm and has been used to treat wounds, ulcers, cutaneous scleroderma and has even been shown to treat cellulite [29–32]. A study by Russell et al. showed that exposing patients to a combination of different LED wavelengths was more effective than monotherapy [33]. A prospective, placebo-controlled, double-blind study using LEDs emitting R (633 nm) and IR (830 nm) light radiation was conducted by Lee et al. [34]. Patients showed statistically significant reductions of wrinkles and increases of skin elasticity in all treatment groups. In a separate study, Goldberg et al. tested a combination of red (633 nm) and infrared (830 nm) LED light on the skin and reported improvements in the softness of periorbital wrinkles in 80 per cent of patients. Histological examination showed evidence of an increased number and thickness of collagen fibres [35]. A similar study conducted in 2012 by Tian et al. showed an increase in type I collagen expression and the number of viable fibroblasts following treatment with various combinations of 630 nm, 830 nm, and other wavelengths of red and IR light [36].

In their focused review, Ferreira et al. found three studies which indicate that PT (physical therapy) combined with SDT (standard drug treatment) promote faster motor function recovery compared to SDT alone between 15 days and one year of follow-up. On the other hand, one study showed that electrical stimulation (electrostimulation) added to the protocol of PT and SDT did not affect treatment outcomes. The current view is that the use of combined SDT and PT in the treatment of Bell's palsy appears to have a positive effect on the rate and speed of recovery

compared with SDT alone [37]. Alayat et al. investigated various forms of physiotherapy, including electrophysical modalities. Patients with Bell's palsy were divided into three groups: 1 – high intensity laser therapy, 2 – low level laser therapy, 3 – facial massage and exercise only. Laser therapy in groups 1 and 2 was applied at eight points on the affected side. Treatment sessions took place three times a week for six consecutive weeks. Outcomes were evaluated at 3 and 6 weeks after the treatment. The authors found that high-intensity laser therapy was the most effective modality. Treatment outcomes were slightly worse in group 2, but still significantly better than in the group of patients who received manual therapy alone [38].

In the field of neuromuscular training (NMT), there are several techniques that have been systematised. Therapeutic strategies should seek a comprehensive solution to the problem, and should be tested and adapted to the symptoms observed in the patient. In approximately 15–20% of patients, permanent sequelae resolve after 3 months of treatment. The effectiveness of facial exercises for paralysis has been discussed in systematic reviews, but the effects are not yet fully understood; still, patients have been reporting improved function and quality of life. There is no evidence of patient deterioration due to any physiotherapy or electrophysical therapy in the treatment of idiopathic facial palsy [39]. In order to clearly assess the hypothesis that facial exercises reduce the recovery time, randomised trials are needed, which is difficult to achieve due to the limited amount of available data. Facial exercise therapy is effective in paralysis for improving appearance, function and to enhance the overall treatment outcome [40].

The interdisciplinary approach combining electrophysical agents and physiotherapy, as presented in this manuscript, is the authors' own methodology, which has been widely used by the co-authors. Such a rapid and successful therapeutic effect can be attributed to the simultaneous application of all the modalities described. Previous attempts to rehabilitate Bell's palsy using monotherapies have produced much less spectacular results.

Further large scale and randomised controlled trials are needed to assess whether these complementary interventions have a significant additive or synergistic effect on complete recovery in patients with Bell's palsy.

Conclusions

The above results confirm the efficacy of ELF-EMF + LED combined with PNF and KT treatments as an adjunct to standard pharmacotherapy. Bell's palsy is often a multidisciplinary problem, and therefore it is important to review the treatment options and strategies that physical medicine and rehabilitation can offer.

Adres do korespondencji / Corresponding author

Danuta Lietz-Kijak

E-mail: danuta.lietzkijak@gmail.com

Abbreviations:

NMT – Neuromuscular Therapy; PNF – Proprioceptive Neuromuscular Facilitation; KT – Kinesiotaping; ELF-EMF – Extremely Low Frequency- Electromagnetic Field; LED – Light Emitting Diode; IR – infrared light; R – red light; PT – Physical Therapy; SDT – Standard Drug Therapy

Piśmiennictwo/ References

- McCaul JA, Cascarini L, Godden D, Coombes D, Brennan PA, Kerawala CJ. Evidence based management of Bell's palsy. *Br J Oral Maxillofac Surg*. 2014; 52 (5): 387–391.
- Baugh RF, Basura GJ, Ishii LE, et al. Clinical practice guidelines: Bell's palsy. *Otolaryngol Head Neck Surg*. 2013; 149 (3): 1–27.
- Glass GE, Tzafetta K. Bell's palsy: A summary of current evidence and referral algorithm. *Fam Pract*. 2014; 31 (6): 631–642.
- De Ru JA, Brennan PA, Martens E. Antiviral agents convey added benefit over steroids alone in Bell's palsy; decompression should be considered in patients who are not recover-ing. *J Laryngol Otol*. 2015; 129 (4): 300–306.
- Pasha R (ed.). *Otolaryngology head and neck surgery: Clinical reference guide*. San Diego. Plural Publishing Inc. 2006.
- House JW, Brackmann DE. Facial nerve grading system. *Otolaryngol Head Neck Surg*. 1985; 93 (2): 146–147.
- Steinhäuser J, Volk GF, Thielker J, Geitner M, Kutenreich, A-M, Klingner CM, Döbel C, Guntinas-Lichius O. Multidisciplinary Care of Patients with Facial Palsy: Treatment of 1220 Patients in a German Facial Nerve Center, *J. Clin. Med*. 2022; 11(2), 427
- Warren TA, Whiteman DC, Porceddu SV, Panizza BJ. Insight into the epidemiology of cutaneous squamous cell carcinoma with perineural spread. *Head Neck*. 2016; 38 (9): 1416–1420.
- Alptekin DÖ. Acupuncture and Kinesio Taping for the acute management of Bell's palsy: A case report. *Complement Ther Med*. 2017 Dec; 35:1-5.
- Di Stadio A, Gambacorta V, Ralli M, Pagliari J, Longari F, Greco A, Ricci G. Facial taping as biofeedback to improve the outcomes of physical rehab in Bell's palsy: preliminary results of a randomized case-control study. *European Archives of Oto-rhino-laryngology: Official Journal of the European Federation of Oto-rhino-laryngological Societies (EUFOS): Affiliated with the German Society for Oto-rhino-laryngology - Head and Neck Surgery*, 17 Jul 2020, 278(5):1693-1698.
- Sun Zai-hui, Tian Yan-ping, Tan Yan-fu, Tao Dan, Li Wen-bo, Ding Ji-lin, Ai Shuang-chun. Effectiveness of Kinesio taping on peripheral facial paralysis. A protocol for systematic review and meta-analysis. *Medicine* 99(46): p e23090, November 13, 2020.
- Tanganelli JP, Oliveira S.s.I, Da Silva T, Porta Santos Fernandes K, Jansiski Motta L, Kalil Bussadori S. Complete and Fast Recovery from Idiopathic Facial Paralysis Using La-ser-Photobiomodulation. March 2020, *Case Reports in Dentistry* 2020(4):1-4.
- Phan NT, Panizza B, Wallwork B. A general practice approach Bell's palsy. *Australian Family Physician*. 2016; 45 (11): 794- 797.
- Pasek J, Pasek T, Sieroń-Stoltny K, Cieślak G, Sieroń A. Electromagnetic fields in medicine – the state of art. *Electromagn. Biol. Med*. 2016; 35 (2): 170-175.
- Adler S, Beckers D, Buck M. *PNF in practice*. Springer. 2008.
- Kase K, Wallis J, Kase T. Clinical therapeutic applications of the Kinesio Taping method. Albuquerque, NM, USA. Kinesio Taping Association International. 2013; 19–72.
- Mostafavifar M, Wertz J, Borchers J. A systemic review of the effectiveness of Kine-sio taping for musculoskeletal injury. *Phys. Sportsmed*. 2012; 40: 33–40.
- Lietz-Kijak D, Ardan R. Physiotherapeutic reduction of orofacial pain using extreme-ly low-frequency electromagnetic field and light-emitting diode therapy - a pilot study. *Pain Research and Management*, 2022
- Valente S.M. Visual disfigurement and depression. *Plast Surg Nurs*. 2004; 24:140-148
- Thomas AW, Graham K, Prato FS, McKay J, Forster PM, Moulin DE, Chari S. A randomized, double-blind, placebo-controlled clinical trial using a low-frequency magnetic field in the treatment of musculoskeletal chronic pain. *Pain Res. Manag*. 2007;12(4):249–258.
- Arneja AS, Kotowich A, Staley D, Summers R, Tappia PS. Electromagnetic fields in the treatment of chronic lower back pain in patients with degenerative disc disease. *Future Science OA*. 2016; 2(1): FSO105.
- Pall ML. Electromagnetic fields act via activation of voltage-gated calcium channels to produce beneficial or adverse effects. *Journal Cell Mol. Med*. 2013; 17(8): 958–965.
- Iannitti T, Fistetto G, Esposito A, Rottigni V, Palmieri B. Pulsed electromagnetic field therapy for management of osteoarthritis-related pain, stiffness and physical function: clinical experience in the elderly. *Clin. Interv. Aging*. 2013; 8:1289–1293.
- Nelson FR, Zvirbulis R, Pilla AA. Non-invasive electromagnetic field therapy produces rapid and substantial pain reduction in early knee osteoarthritis: a randomized double-blind pilot study. *Rheumatol. Int*. 2013; 33(8): 2169-73.
- Lietz-Kijak D, Kijak E, Śliwiński Z, Opalko K. The use of physiotherapy in the re-generation of periapical bone structures of the teeth, prepared to load the prosthetic. *Progression of hygiene and experimental medicine* 2013; 67:643 – 647.
- Calderhead RG, Won-Serk K, Ohshiro T, Trelles MA, Vasily DB. Adjunctive 830 nm light-emitting diode therapy can improve the results following aesthetic procedures. *Laser Ther*. 2015; 24(4): 277–289.
- Barolet DB. Light-emitting diodes (LEDs) in dermatology. *Semin. Cutan. Med. Surg*. 2008; 27:227–238.
- Simpson CR, Kohl M, Essenpreis M, et al. Near infrared optical properties of ex-vivo human skin and subcutaneous tissues measured using the Monte Carlo inversion technique. *Phys. Med. Biol*. 1998; 43: 2465–2478.
- Horwitz LR, Burke TJ, Carnegie D. Augmentation of wound healing using mono-chromatic infrared energy: exploration of a new technology for wound management. *Adv. Wound Care*. 1999; 12: 35–40.
- von Felbert V, Kerland-Lang K, Hoffmann G, Wienert V, Simon D, Hunziker T. Irradiation with water-filtered infrared A plus visible light improves cutaneous scleroderma lesions in a series of cases. *Dermatology*. 2011; 222: 347–357
- Paolillo FR, Borghi-Silva A, Parizotto NA, et al. New treatment of cellulite with in-fared-LED illumination applied during high-intensity treadmill training. *Journal Cosmet. Laser Ther*. 2011; 13:166–171.
- Petrini M, Spoto G, Scarano A, D'Arcangelo C, Tripodi D, Di Fermo P, D'Ercole S. Near-infrared LEDS provide persistent and increasing protection against *E. faecalis*. *J Photochem Photobiol B*. 2019 Aug; 197:111527. Epub 2019 Jun 4. PMID: 31226527.
- Russell BA, Kellett N, Reilly LR. A study to determine the efficacy of combination LED light therapy (633nm and 830nm) in facial skin rejuvenation. *J. Cosmet. Laser Ther*. 2005; 7(3-4): 196–200.
- Lee SY, Park KH, Choi JW, et al. A prospective, randomized, placebo-controlled, double-blinded, and split-face clinical study on LED phototherapy for skin rejuvenation: clinical, profilometric, histologic, ultrastructural, and biochemical evaluations and comparison of three different treatment settings. *Journal Photochem. PhotoMol. B*. 2007; 88:51–67.
- Goldberg DJ, Amin SA, Russell BA, et al. Combined 633 nm and 830 nm LED treatment of photoaging skin", *Journal Drugs Dermatol*. 2006; 5:748–753.
- Tian YS, Kim NH, Lee AY. Antiphotaging effects of light-emitting diode irradiation on narrow-band ultraviolet B-exposed cultured human skin cells. *Dermatol. Surg*. 2012; 38:1695–1703.
- Ferreira M, Marques EE, Duarte JA, Santos PC. Physical therapy with drug treatment in Bell palsy: a focused review. *American Journal of Physical Medicine & Rehabilitation*. 2015; 94 (4): 331-340.
- Alayat MS, Elsdany AM, El Fiky AA. Efficacy of high and low level laser therapy in the treatment of Bell's palsy: a randomized double blind placebo-controlled trial. *Lasers in medical science*. 2014; 29 (1): 335-342.
- Pereira LM, Obara K, Dias JM, Menacho MO, Lavado EL, Cardoso JR. Facial exercise therapy for facial palsy: systematic review and meta-analysis. *Clinical rehabilitation*. 2011; 25 (7): 649-658.
- Matos C. Peripheral facial paralysis. The role of physical medicine and rehabilitation. *Acta Medica Portuguesa*. 2011; 24 (4): 907-914.