

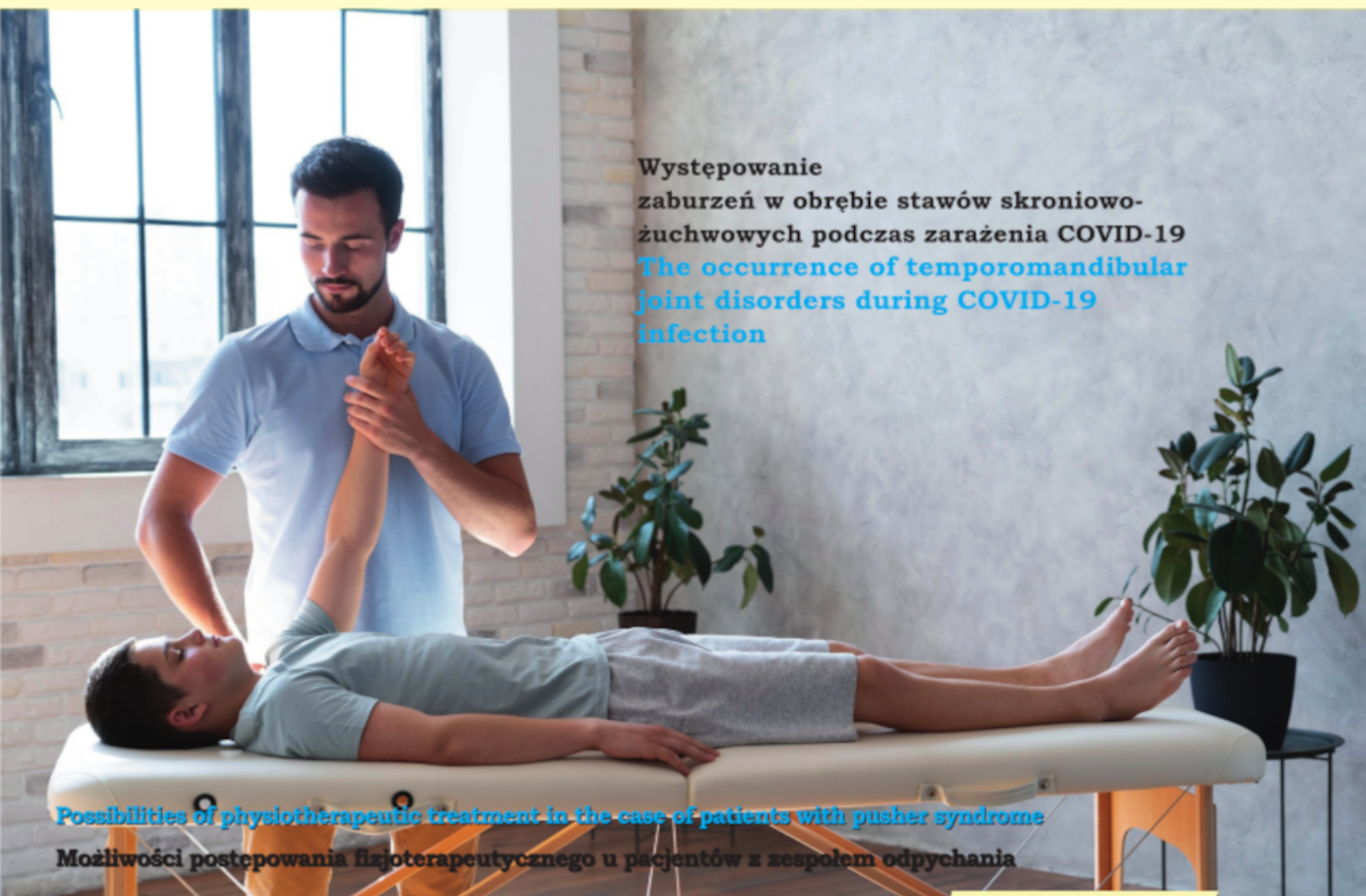fizjoterapia polska

POLISH JOURNAL OF PHYSIOTHERAPY

OFICJALNE PISMO POLSKIEGO TOWARZYSTWA FIZJOTERAPII

THE OFFICIAL JOURNAL OF THE POLISH SOCIETY OF PHYSIOTHERAPY

NR 3/2023 (23) KWARTALNIK ISSN 1642-0136



**Występowanie
zaburzeń w obrębie stawów skroniowo-
żuchwowych podczas zarażenia COVID-19**
**The occurrence of temporomandibular
joint disorders during COVID-19
infection**

Possibilities of physiotherapeutic treatment in the case of patients with pusher syndrome

Możliwości postępowania fizjoterapeutycznego u pacjentów z zespołem odpychania

ZAMÓW PRENUMERATĘ!

SUBSCRIBE!

www.fizjoterapiapolska.pl

www.djstudio.shop.pl

prenumerata@fizjoterapiapolska.pl





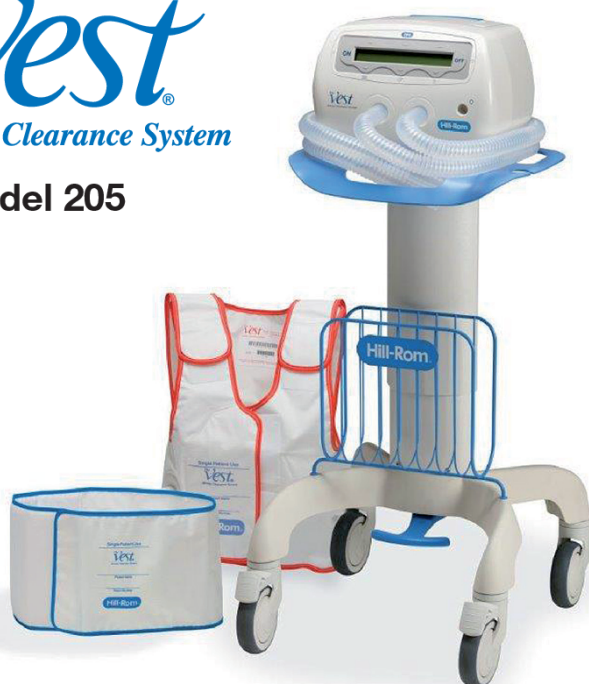MATIO sp. z o.o.

to sprawdzony od 7 lat dystrybutor
urządzeń do drenażu dróg oddechowych
amerykańskiej firmy Hillrom

Hill-Rom.

The
Vest
Airway Clearance System

model 205



MetaNeb™



sprzęt medyczny do drenażu i nebulizacji dla pacjentów w warunkach szpitalnych
– ze sprzętu w Polsce korzysta wiele oddziałów rehabilitacji i OIOM

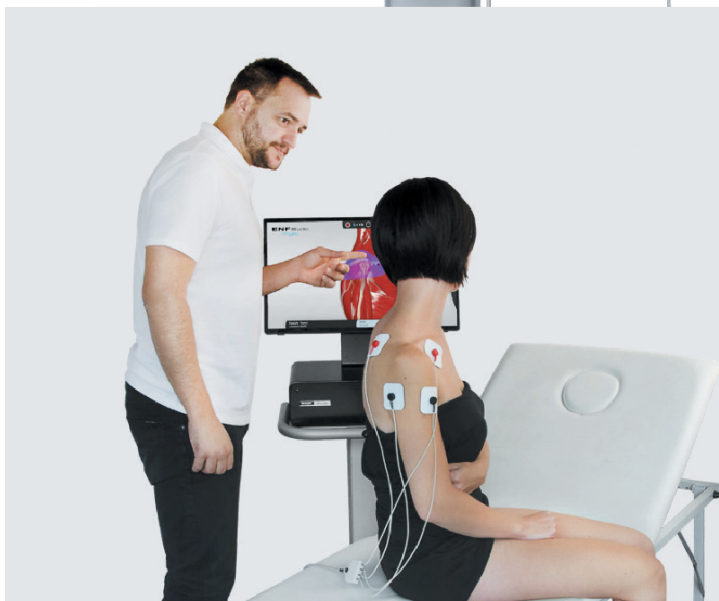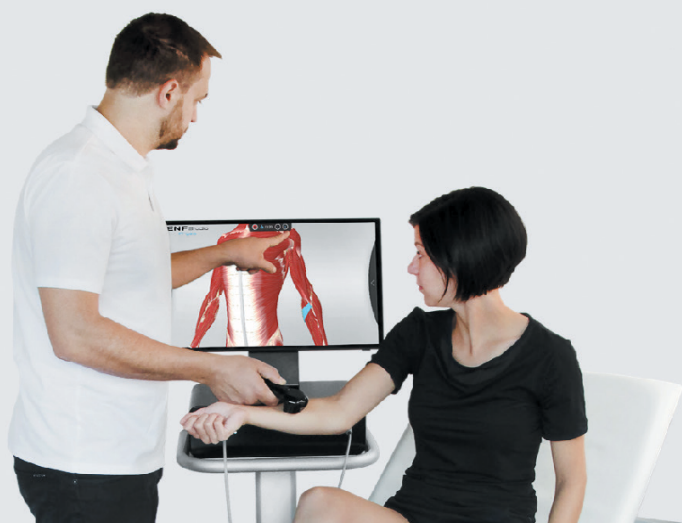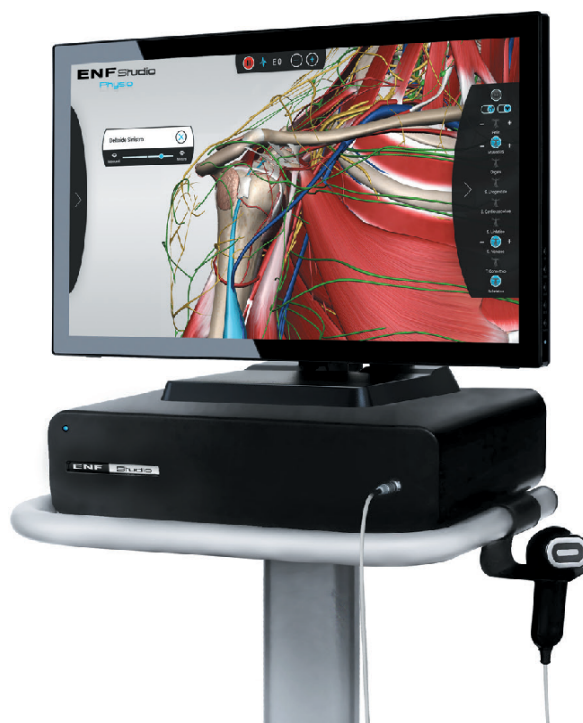MATIO sp. z o.o., ul. Celna 6, 30-507 Kraków, tel./fax (+4812) 296 41 47,
tel. kom. 511 832 040, e-mail: matio_med@mukowiscydoza.pl, www.matio-med.pl

Terapia ENF

Kompleksowy system oceny i fizjoterapii

- autoadaptacyjna fizjoterapia
- obiektywna ocena stanu tkanek
- biofeedback w czasie rzeczywistym
- gotowe protokoły terapeutyczne
- wszechstronne zastosowanie
- anatomia 3D
- mapy 3D

www.enf-terapia.pl



Aktualna i praktyczna wiedza!



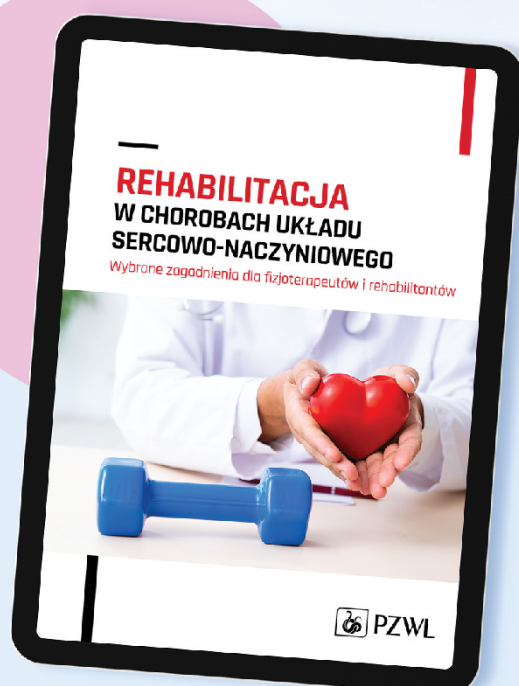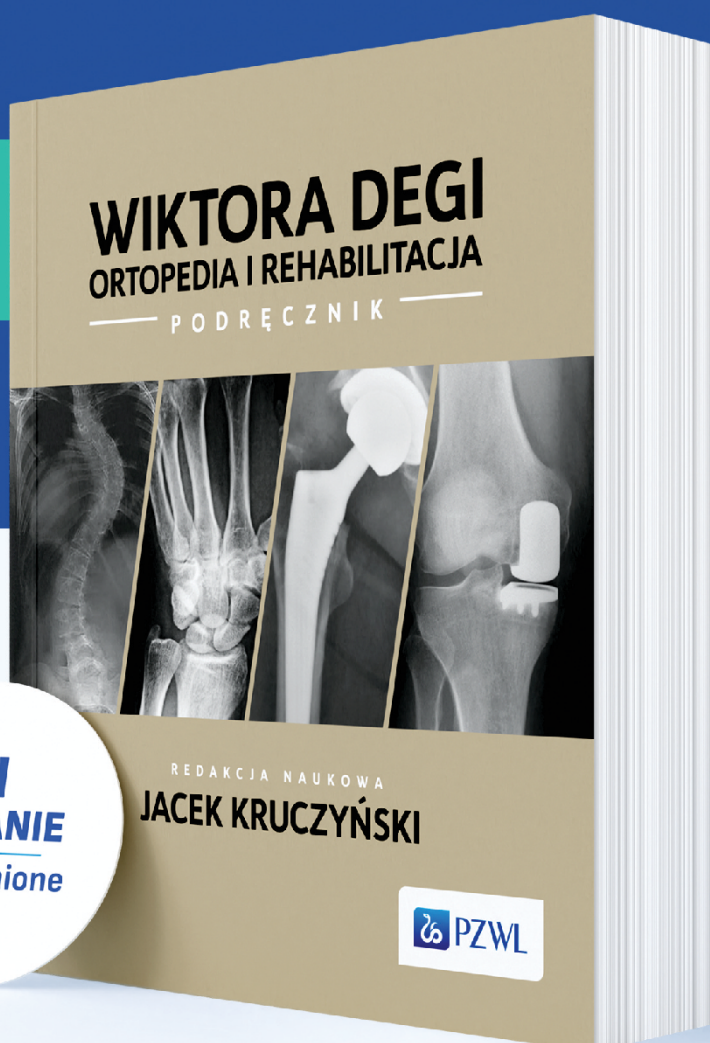ponad
800 rycin
i 1 tys. stron

dodatkowe
materiały
multimedialne



szukaj na pzwl.pl

**III
WYDANIE**
uaktualnione



**POBIERZ
DARMOWY E-BOOK**
od PZWL w prezencie!



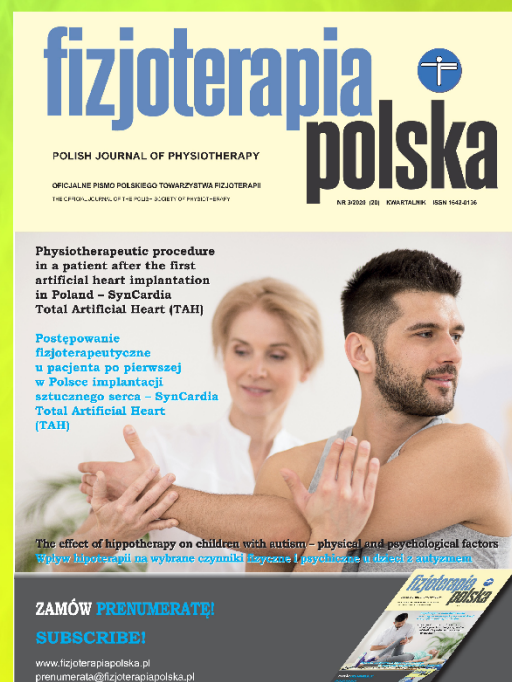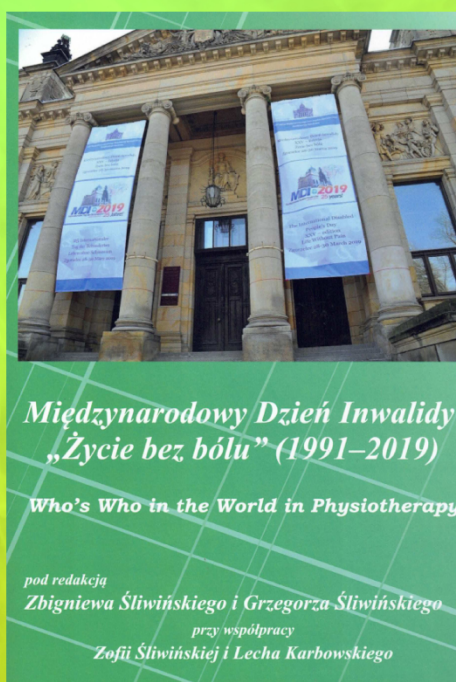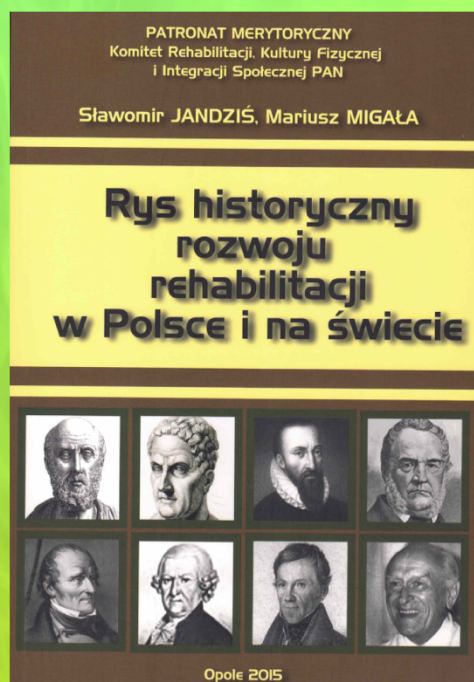
fizjoterapia polska



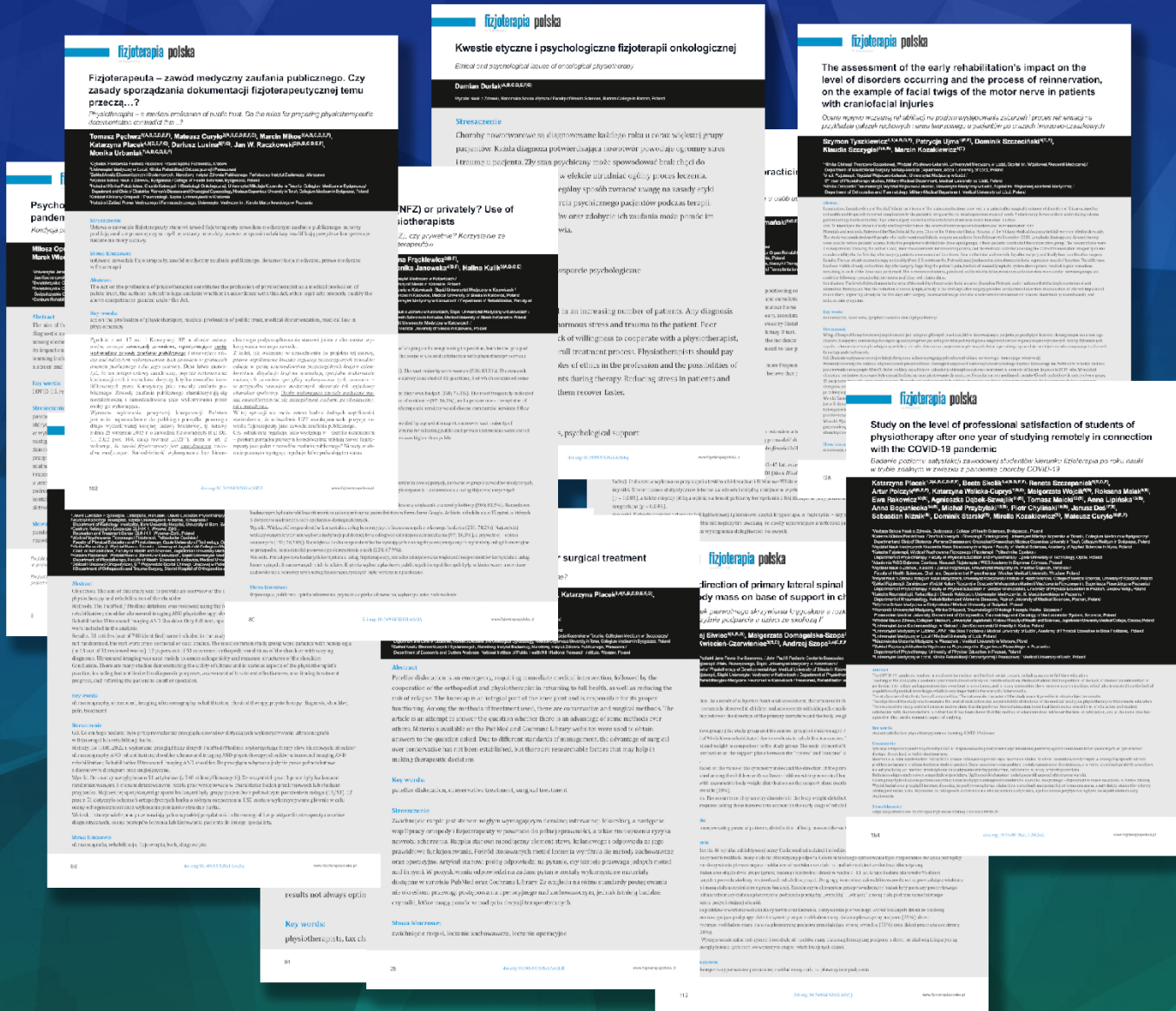sklep internetowy:
www.djstudio.shop.pl

w sklepie dostępne między innymi:


- *archiwalne numery Fizjoterapii Polskiej w wersji papierowej*
- *artykuły w wersji elektronicznej*
- *książki poświęcone fizjoterapii*
- *prenumerata Fizjoterapii Polskiej*



**Rabat 15% na pojedyncze artykuły
w j. polskim z czasopisma
Fizjoterapia Polska w sklepie
DJ Studio**



djstudio.shop.pl
15% z kodem
FP3-2023-ART
o 30 września 2023



Rok założenia firmy 1996
www.butterfly-mag.com
tel. 85 743 22 21
kom. 603 299 035



BIOMAGNETOTERAPIA W WYROBACH MEDYCZNYCH „ORT BUTTERFLY”

- BEZ BÓLU, STRESU I BEZ TABLETEK!
- LECZYSZ SIĘ NATURALNIE
- ŚPIĄC, PRACUJĄC, WYPOCZYWAJĄC...
- USUWASZ BÓL I JEGO PRZYCZYNĘ!
- TERAPIA STARA JAK ŚWIAT!
- SPRAWDZA SIĘ I DAJE RADĘ W NIERÓWNEJ WALCE Z PANDEMIĄ – COVID 19!

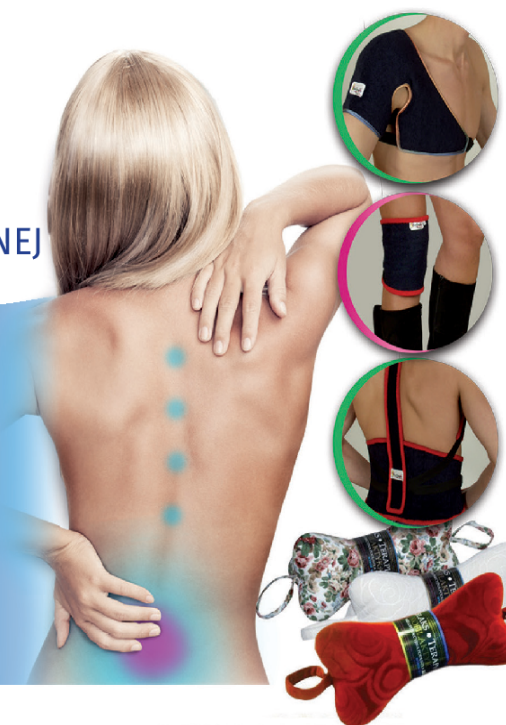REGULARNA BIOSTYMULACJA MAGNETYCZNA!

Ogromny potencjał Natury w zwalczaniu smogu energetycznego i autooksydacji, będącej główną przyczyną wszystkich chorób cywilizacyjnych!

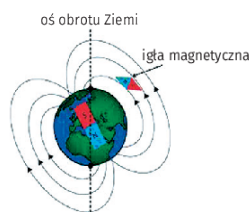
Najstarsza Terapia Świata wspomagająca każdą formę leczenia!

Uważa się do dziś, że bez niej nie da się wyleczyć żadnej choroby do końca!

Naturalna Terapia Magnetyczna Twoje Zdrowie, Twoja Uroda, Odporność i Sprawność do późnej starości! **Wypróbuj** – gdy zawiodły już inne terapie!



Biomagnetoterapia inicjuje ożywienie komórkowe, oczyszcza i „odmładza” krew, podnosząc vitalność całego organizmu, który uruchamia intuicyjne procesy obronne, znosząc dyskomfort powodowany bólem, urazem lub stresem, bez konieczności ostrej dawki leków chemicznych...



DLACZEGO CHORUJEMY?

Natężenie sztucznych pól elektromagnetycznych zwiększyło się 100 tys. razy! Naturalne pole magnetyczne Ziemi zmniejszyło swą moc o połowę!



BIOMAGNETYZM - jako antidotum; jedyne i absolutne; na cancerogenną ekspansję „smogu energetycznego”!

ZŁOTE LOGO
Międzynarodowych Targów
Rehabilitacja
Łódź IX/2007



Jestem osobistym królikiem doświadczalnym! I żyję – realizując 25 lat wciąż nowe i śmielsze pomysły w wykorzystaniu tej **boskiej energii** naturalnych magnesów! Dzięki nim pokonuję dziś niezliczone przeszkody i przeciwności losu z nieznaną mi przedtem energią i determinacją! To moja pasja! I przeznaczenie!

Najnowsza opinia klienta:

Komentarz ten jest moim osobistym świadectwem zadowolenia z produktów biomagnetycznych „Ort Butterfly”, których używam od 20. lat! Zastanawiam się, zwłaszcza nad fenomenem poduszki (określenie nie jest przypadkowe) zwyczajnie; nie wyobrażam sobie snu i wypoczynku bez magnetycznej „Ort Butterfly” – pod głowę! Jej ergonomiczny, przyjazny dla głowy i szyi kształt sprawia, że wysypiam się „po królewsku”. Zabieram ją również ze sobą w bliższe i dalsze podróże! Czyż gdyby była to zwyczajna poduszka, fundowałbym sobie dodatkowy bagaż? Wychwalam więc ją od zarania, polecam i rekomenduję, bo jest tego warta! Bez niej nie wyobrażam sobie prawdziwie relaksacyjnego snu i błogiego, kojącego wypoczynku! Dziękuję, że ją Pani stworzyła!

J. Szew. Działdowo (maj 2020)

PS Poduszki „Ort Butterfly” to prawdziwe arcydziełka robione z wyczuciem i sercem... jak rzeźby Michała Anioła... Polecam wszystkim!

ŚRODKIEM DO CELU

- pewność że dziecko jest nakarmione
- więcej czasu na wspólną zabawę z dzieckiem
- szansa na lepsze efekty rehabilitacji

Jeśli występują problemy z żywieniem (np. problemy z motoryką jamy ustnej, konieczność modyfikacji konsystencji diety, ograniczony apetyt), skonsultuj się z naszym Ekspertem.

Skontaktuj się z naszym Ekspertem i dowiedz się więcej na temat:

- konsekwencji wynikających z niedożywienia
- wskazań do żywienia dojelitowego
- dokumentów niezbędnych do rejestracji w poradni żywieniowej
- dokarmiania przez zgłąbnik
- najbliższej poradni żywieniowej

Mgr Iwona Widera

Specjalista pielęgniarstwa psychiatrycznego.
Ekspert do spraw żywienia dojelitowego dzieci
oraz osób dorosłych.

Zadzwoń: 698-945-066



- Szczegółowa lista poradni żywieniowych, realizujących świadczenie żywienia dojelitowego w warunkach domowych na stronie: www.pelnaporcjaopieki.pl



WAŻNE:
Świadczenie
objęte pełną
refundacją NFZ



RABAT NA WSZYSTKIE KSIĄŻKI WYDAWNICTWA EDRA URBAN & PARTNER W KSIĘGARNI DJ STUDIO



w tym:

Wielka Fizjoterapia tomy 1-3
djstudio.shop.pl

10% z kodem FP-3-23-EDRA
do 30 września 2023



zabezpiecz się przed potencjalnymi **roszczeniami** **pacjentów**

program ubezpieczeń dla fizjoterapeutów
pod patronatem PTF

dla kogo?

Zarówno dla fizjoterapeutów prowadzących własną działalność w formie praktyki zawodowej, podmiotu leczniczego jak również tych, którzy wykonują zawód wyłącznie na podstawie umowy o pracę lub umowy zlecenie.

co obejmuje program ubezpieczeń?

- igłoterapie
- zabiegi manualne (mobilizacje i manipulacje)
- leczenie osteopatyczne
- naruszenie praw pacjenta i szkody w mieniu pacjentów

oraz szereg innych rozszerzeń ukierunkowanych na zawód fizjoterapeuty



kontakt w sprawie ubezpieczeń:

Piotr Gnat

+48 663 480 698

piotr.gnat@mentor.pl

[linkedin.com/in/piotrgnat](https://www.linkedin.com/in/piotrgnat)

ubezpiecz się **on-line** na **PTFubezpieczenia.pl**

Cryotherapy versus corticosteroid phonophoresis in the treatment of keloid scars: A randomized clinical trial

*Porównanie krioterapii i fonoforezy kortykosteroidowej w leczeniu blizn keloidowych:
Randomizowane badanie kliniczne*

**Mai Mahmoud Abo Sabee^{1(A,B,C,D,E,F)}, Amal Mohamed Abd El Baky^{1(A,B,C,D,E,F)},
Tarek Ahmed Amer^{2(A,B,C,D,E,F)}, Nessrin Afify Abd El Rasheed^{1(A,B,C,D,E,F)}**

¹Department of Physical Therapy for Surgery, Faculty of Physical Therapy, Cairo University, Giza, Egypt

²Department of Plastic Surgery, Faculty of Medicine, Cairo University, Giza, Egypt

Abstract

Background. Keloid scars negatively impact patients' physical and mental well-being, causing pain and itching. Several methods exist for treating keloids by modulating and improving scar characteristics.

Purpose. To investigate and compare the effects of cryotherapy and corticosteroid phonophoresis on patients with keloid scars.

Methods. This was a randomized clinical trial. Sixty patients, both male (28) and female (32), with keloid scars were divided into two equal groups. Group A received cryotherapy for 12 weeks ($n = 30$), while Group B underwent corticosteroid phonophoresis for the same duration ($n = 30$). Assessments were made pre-treatment, after 6 weeks, and after 12 weeks of treatment.

Results. Post-treatment comparisons between the two groups revealed statistically significant reductions in VSS at both 6 weeks and 12 weeks in favor of Group A ($p < 0.05$).

Conclusion. Cryotherapy demonstrated a significantly greater positive impact on scar measurements in patients with keloid scars than corticosteroid phonophoresis.

Keywords:

cryotherapy, phonophoresis, keloid scars

Streszczenie

Wstęp. Blizny keloidowe negatywnie wpływają na fizyczne i psychiczne samopoczucie pacjentów, powodując ból i świąd. Istnieje wiele metod leczenia blizn keloidowych poprzez modulację i poprawę ich charakterystyki.

Cel. Badanie i porównanie efektów krioterapii i fonoforezy kortykosteroidowej u pacjentów z bliznami keloidowymi.

Metody. Badanie było randomizowanym badaniem klinicznym. Sześćdziesięciu pacjentów - zarówno mężczyzn (28) jak i kobiet (32) z bliznami keloidowymi - podzielono na dwie równe grupy. Grupa A otrzymywała krioterapię przez 12 tygodni ($n = 30$), podczas gdy Grupa B była poddawana fonoforezie kortykosteroidowej przez ten sam okres czasu ($n = 30$). Oceny przeprowadzono przed leczeniem, po 6 tygodniach i po 12 tygodniach leczenia.

Wyniki. Porównania po leczeniu między dwiema grupami wykazały istotne statystycznie zmniejszenie VSS zarówno po 6 tygodniach, jak i po 12 tygodniach leczenia na korzyść Grupy A ($p < 0,05$).

Wnioski. Krioterapia wykazała znacząco lepszy wpływ na pomiary blizn u pacjentów z bliznami keloidowymi niż fonoforeza kortykosteroidowa.

Słowa kluczowe:

krioterapia, fonoforeza, blizny keloidowe

Introduction

Keloid scars represent a major morbidity source for burned patients and can cause a variety of lifestyle-restricting symptoms, such as pain, pruritus, burning, contractures, and stiffness [1].

Keloid scars are equally prevalent in both sexes with the highest frequency in the second and third decades. Their incidence ranges from 40% to 70% postoperative to 91% post burns, according to the wound's depth [2]. A keloid forms due to the skin's abnormal reflection of a wound or an injury. The most common causes are: after exposure to burns, surgical incisions, acne, chickenpox, other dermatological diseases that cause remaining scars, injuries after shaving or piercings [3]. Compression therapy, intralesional or topical corticosteroids, excisional surgery, radiation, laser therapy, silicone gel sheeting, cryotherapy, and other approaches can be used as a single or combined therapeutic methods for keloid scars [4]. Conservative methods are preferred to slow the progression of scarring and contractures due to their non-invasiveness [5].

Cryotherapy is an outpatient procedure that can be performed in a clinic or minor procedure room [6]. It causes quite pain, so some patients may need local anesthesia for its application [7]. Keloids whose depth is less than 6 mm flatten when they are frozen, and show good outcomes [8].

Corticosteroids are widely used as first line therapy for keloid management. They are successful in reducing keloid formation through their anti-inflammatory effects, as well as lowering synthesis of collagen and glycosaminoglycan and increasing degeneration of collagen and fibroblasts [9, 10].

Phonophoresis is an approach for increasing drug permeation through the skin. It is a combination of ultrasound and topical drug therapies to achieve therapeutic drug concentrations at specific skin sites [11]. It has several advantages, including a low risk of skin burning and the elimination of the need to ionize the drug. The following ultrasound parameters were used to treat keloids: 1 MHz frequency, 0.5 W/cm² intensity, 5 minute treatment duration [12].

The lack of primary related studies and research on the role of physical therapy in the treatment of keloids scars and abnormal healing processes necessitated this study. Unfortunately, there is a divergence of opinion regarding the best physical therapy strategy for treating keloid scars. As a result, the current study attempted to determine the best type of treatment for keloid scars.

Materials and methods

Study design

The study was designed as a randomized controlled trial. It received approval from the Ethical Committee its No:P.T.REC/012/002907, Faculty of Physical Therapy, Cairo University, Egypt. It based on the principles of the Helsinki Declaration for human research. The clinical part of study took place between January 2022 and March of 2023. All patients were asked to sign a consent form for ethical issues.

Participants

Sixty patients (28 males and 32 females) with keloid scars were recruited from Al-kasr Eleiny and Soad Kafafy Teaching

Hospitals. They were referred by a physician if they met the following criteria: age ranged from 20 to 40 years; they had keloid scars in any area of the body; and they experienced pain, unpleasant sensation and dysfunction as a result of keloid scars. Exclusion criteria were mental or psychological disorders, any systemic disease, thyroid gland disease, circulatory disorders, a history of skin cancer in the treated area, an open wound at or close to treated area, or scarring on the genitalia. In addition, patients receiving steroids, radiation therapy, or chemotherapy were excluded from the study.

Randomization

The nature, aim, and benefits of the current study were explained to each patient, along with their right to withdraw or decline at any time, and the confidentiality of any gathered information. A computer-based randomization program divided the patients into two equal-sized groups (A & B) [13]. After randomization, there was no subject withdrawal from the study (Figure 1).

Interventions

Group (A) consisted of 30 patients (14 males and 16 females) receiving cryotherapy for 12 weeks. Group (B) consisted of 30 patients (14 males and 16 females) receiving corticosteroid phonophoresis for 12 weeks.

Cryotherapy

Each participant in group (A) received cryotherapy (–22°C), using hand held cryosurgical unit, once every 3 weeks, for 12 weeks. The patient was positioned in proper sitting, and the keloid was cleaned with cotton and alcohol. Adhesive putty (clay) was used to cover nearby structures to provide protection. Two 15-second freeze cycles were administered to patients using the spot freeze technique. The field was divided into overlapping circles of 2 cm each in cases of larger lesions. Then, each circle was separately treated [14].

Corticosteroid phonophoresis

Each participant in group (B) received corticosteroid phonophoresis, 3 sessions/week, for 12 weeks, with a total sessions of 36 sessions. The patient was positioned in proper sitting, and the keloid was cleaned with cotton and alcohol. The applied phonophoresis parameters were 1 MHz frequency, 0.5 W/cm² intensity, and 5 minute duration. The corticosteroid was combined with conducting media gel and was directly applied to the cleaned surface of keloid. Then, the ultrasonic head was placed in a continuous circular motion for 5 minutes on the keloid surface [12]. A thin film of coupling medium (gel) was put on the keloid scar and a sufficient quantity of 1.5 ml triamcinolone was applied with a syringe over each 5 cm of the scar; then the ultrasound was implemented by the therapist [15].

Outcome measures

Vancouver Scar Scale (VSS)

It was used to evaluate the alterations in scar appearance for all patients in both groups before, after 6 weeks and after 12 weeks of treatment. It evaluated vascularity, thickness, pliability, and pigmentation of the keloid scarring. The VSS is widely used in burn studies to assess treatment and as an outcome measure [16].

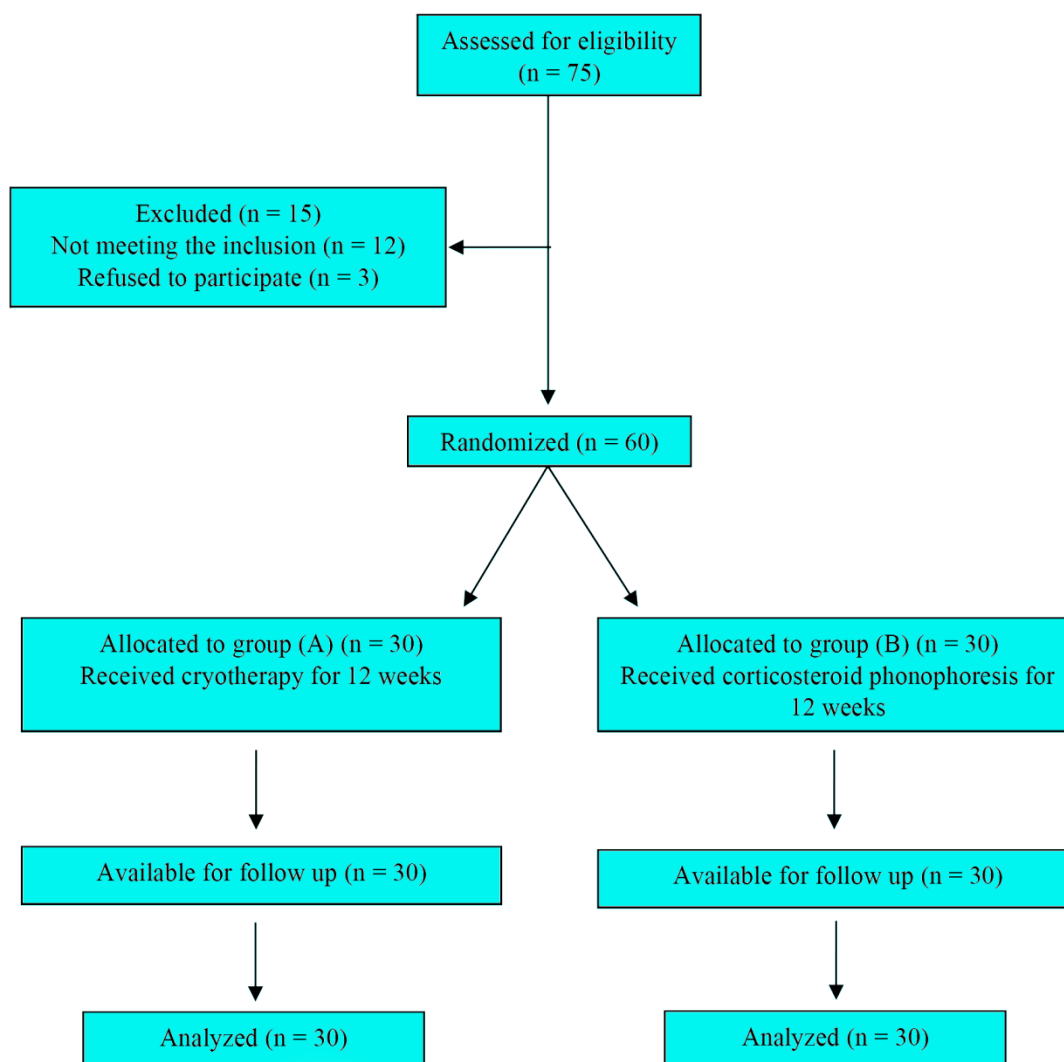


Figure 1. Participants' flow Chart

Statistical analysis

Statistical analysis was performed using SPSS for windows, version 25 (SPSS, Inc., Chicago, IL). The current test included two independent variables. The first was the (tested group); between subject factor which had two levels (group (A) received cryotherapy and group (B) received corticosteroid phonophoresis). The second was the (measuring periods); within subject factor which had three levels (pre-treatment, post 6 weeks of treatment, and post 12 weeks of treatment). Additionally, Changes in scar appearance were assessed by Vancouver Scar Scale (VSS). Data were checked for normality assumption, homogeneity of variance, and presence of extreme scores before final analysis. This check was carried out as a prerequisite for parametric analysis. The results of a descriptive analysis using histograms and the normal distribution curve demonstrated that changes in scar appearance using VSS had normal distribution and did not violate the parametric assumption for the tested dependent variables. There was also no significant difference with p values > 0.05 when the homogeneity of variance was tested. Outliers were checked using box and whiskers plots of the tested variable, but none were found. The Shapiro-Wilk test was used to determine the

normality of the data, which showed normal distribution for the changes in scar appearance using VSS. Therefore, comparison of the tested variables of interest at various tested groups and measuring periods was carried out using 2×3 mixed design MANOVA. The initial alpha level was set at 0.05.

Result

At baseline, both groups showed statistically non-significant differences in age, sex, body mass, height, and body mass index (BMI), as well as all outcome measures ($p > 0.05$) (Table 1, 4). Within group (A), Multiple pairwise comparisons (Post hoc tests) revealed statistically significant of changes in scar appearance by Vancouver Scar Scale (VSS) at different measuring periods ($p < 0.05$) (Table 2).

Within group (B), Multiple pairwise comparisons (Post hoc tests) revealed a statistically significant reductions at different measuring periods ($p < 0.05$) (Table 2).

Comparing both groups regarding VSS revealed statistically non-significant differences at pre-treatment ($p > 0.05$), while they revealed statistically significant reductions at post 6 weeks and post 12 weeks of treatment in favor of group (A) ($p < 0.05$) (Table 3).

Table 1. Physical characteristics of patients in both groups

	Group (A) (n = 30)	Group (B) (n = 30)	P value
Age [yrs.]	29.3 ± 6.24	27.03 ± 5.54	0.143 NS
Sex			
Male	14 (46.67%)	14 (46.67%)	1.00 NS
Female	16 (53.33%)	16 (53.33%)	
Body mass [kg]	75.73 ± 13.15	76.66 ± 12.3	0.778 NS
Height [m]	1.69 ± 0.086	1.66 ± 0.078	0.150 NS
BMI [kg/m ²]	26.25 ± 4.44	26.47 ± 6.28	0.872 NS

Table 2. Descriptive statistics and 2×3 mixed design MANOVA for VSS at different measuring periods within group (A) comparative to group (B)

	Pre treatment (Mean ± SD)	Post 6 weeks of treatment (Mean ± SD)	Post 12 weeks of treatment (Mean ± SD)
VSS (group A)	8.13 ± 2.95	3.93 ± 1.57	1.43 ± 1.13
VSS (group B)	8.8 ± 2.69	7.5 ± 2.44	6.73 ± 2.33
<i>Multiple pairwise comparisons (Post hoc tests) among different measuring periods for all outcome measures within group (A)</i>			
p-value	Pre Vs. Post 6 weeks of treatment Pre Vs. Post 12 weeks of	treatment Post 6 weeks of treatment Vs.	Post 12 weeks of treatment
VSS (group A)	0.0001*	0.0001*	0.0001*
VSS (group B)	0.0001*	0.0001*	0.0001*

Table 3. Multiple pairwise comparison tests (Post hoc tests) for VSS between both groups at different measuring periods

Group (A) Vs. Group (B)	Pre treatment	Post 6 weeks of treatment	Post 12 weeks of treatment
VSS	0.365	0.0001*	0.0001*

Discussion

Over millions of years, a scar-forming process has evolved with the goal of restoring functionality rather than aesthetic appeal. Some people experience an abnormal healing process that leads to excessive scarring that may extend beyond the wound's original boundaries, creating a huge, troublesome cosmetic flaw. Such keloid scars may cause pruritis, pain, and functional loss, and they may place a heavy psychosocial burden on the patient [17]. Therefore, this study conducted to investigate and compare the effects of cryotherapy and corticosteroid phonophoresis on Vancouver scar scale in patients with keloid scars.

To the author's knowledge, no previous research compared the

effects of cryotherapy and phonophoresis in patients with keloid scars. The primary outcome of the current study was that cryotherapy reduced Vancouver scar scale measures in patients with keloid scars. Consequently, the results of the current study offer preliminary support for the premise that cryotherapy could benefit these patients. These findings are consistent with previous studies, which reported that cryotherapy is beneficial in treating keloid scars.

The outcomes are in agreement with those noted by (O'Boyle et al.); (Barara et al.) and (Rusciani et al.).

Our results tie well with previous studies of O'Boyle et al. [18] who indicated the efficacy and safety of cryotherapy in treating

keloid scars, with minor side effects. Additionally, Barara et al. [13] reported the effectiveness of cryotherapy in keloid treatment, with thickness and duration of keloid representing the most critical factors affecting treatment outcome. Moreover, Rusciani et al. [19] revealed the valuable effect of cryotherapy on achieving complete keloid flattening, with a low-risk and a low-recurrence rate.

While the results are in disagreement with those reported by van Leeuwen et al. [20] who noted that, cryotherapy received a grade C recommendation from the American Society of Plastic Surgeons as a result of inconsistent and limited evidence regarding its efficacy in treating keloid scars.

The contrast among studies could be related to the variations in the used definition to discriminate keloid scars, cryotherapy application, and the tools used in quantifying outcome measures.

The valuable effect of cryotherapy on destructing keloid scars could be attributed to two phases of cellular destruction, including physical and vascular phases. In the physical phase, rapid freezing triggers direct cell injury via sharp ice crystals formation. In addition, the differential freezing of cell compartments causes alterations of osmotic gradients and imbalances of electrolyte, leading to irreversible cellular damage. During the vascular phase, damage to and failure of the microcirculation cause ischemic necrosis and result in cellular destruction [21, 22]. The mechanisms through which cryotherapy prevents recurrence of keloids could be explained from two viewpoints. Firstly, histopathological examination has proven that cryotherapy produces scar tissue rejuvenation. Freezing of pathological scar tissues causes abnormal keloid fibroblasts to differentiate toward a normal phenotype. Cryotherapy has been revealed to normalize the keloidal fibroblasts' synthetic activity in vitro. Following treatment, type III to type I collagen ratio increases, emulating normal healthy tissue. Secondly, the lack of wound contraction after a freezing injury may represent an additional mechanism. Wound contraction in burns causes severe scarring and contractions. Nevertheless, no wound contraction is observed after freezing [23, 24]. After cryotherapy, the cellular matrix persists and serves as a scaffold for regeneration of cells, boosting wound repair. Such mechanism may inhibit the recurrence, because high-tension wounds are suitable to keloid formation [25].

In our current study, we must explain that corticosteroid phonophoresis was also effective but with unsatisfactory results

compared to cryotherapy and other treatment modalities. This result also concluded in the following study (Wahba et al.,).

These findings came in line with Wahba et al. [12] who found that corticosteroid phonophoresis resulted in significant reductions in the total score of VSS at post 24 weeks of treatment when compared with pre-treatment and post 12 weeks of treatment. In addition, a significant reduction was observed post 12 weeks of treatment when compared with pre-treatment.

The beneficial effect of corticosteroid phonophoresis on reducing the VSS scores could have several explanations. First, it suppresses inflammation via preventing migration and phagocytosis of leukocytes and monocytes. Second, the strong vasoconstriction caused by corticosteroids restricts the delivery of nutrients and oxygen to the wound area. Finally, the antimitotic impact suppresses keratinocytes and fibroblasts, delaying the development of new epithelia and collagen. Summarized, by reducing the inflammatory response in the wound, decreasing proliferation of fibroblasts, and inducing hypoxia, corticosteroids appear to restrict collagen formation [26].

Comparing both groups post-treatment revealed statistically significant reductions in VSS scores at post 6 weeks and post 12 weeks of treatment in favor of group (A). The review of literature did not find any research highlighting the effect of cryotherapy versus corticosteroid phonophoresis on VSS in patients with keloid scars. The current study is therefore regarded as the pioneering investigation into this topic. Accordingly, the results cannot be compared or discussed with other research findings but indicated the better effect of cryotherapy on VSS in patients suffering from keloid scars.

The main limitation of the current study is the lack of a follow-up of the keloid scars among the examined groups following the end of interventions by several months to assess the long-term impact.

Conclusion

Cryotherapy reduced vancouver scar scale measures in patients with keloid compared to corticosteroid phonophoresis.

Adres do korespondencji / Corresponding author

Mai Mahmoud Abo Sabee

E-mail: mai.sherief09@gmail.com

Acknowledgement

The authors would like to thank all individuals who participated in this study.

Piśmiennictwo/ References

1. Friedstat JS, Hultman CS. Hypertrophic burn scar management: what does the evidence show? A systematic review of randomized controlled trials. *Ann Plast Surg.* 2014; 72(6): S198-201.
2. Gauglitz GG, Korting HC, Pavicic T, Ruzicka T, Jeschke MG. Hypertrophic scarring and keloids: pathomechanisms and current and emerging treatment strategies. *Mol Med.* 2011; 17(1-2): 113-125.
3. Atiyeh BS (2007). Nonsurgical management of hypertrophic scars: evidence-based therapies, standard practices, and emerging methods. *Aesthetic plastic surgery* 31(5): 468-492.
4. Tsao SS, Dover JS, Arndt KA, Kaminer MS. Scar management: keloid, hypertrophic, atrophic, and acne scars. *Semin Cutan Med Surg.* 2002; 21(1): 46-75.

5. Anthonissen M, Daly D, Janssens T, Van den Kerckhove E. The effects of conservative treatments on burn scars: a systematic review. *Burns*. 2016; 42(3): 508–518.
6. Mitchell MF, Tortolero-Luna G, Cook E, Whittaker L, Rhodes-Morris H, Silva E. A randomized clinical trial of cryotherapy, laser vaporization, and loop electrosurgical excision for treatment of squamous intraepithelial lesions of the cervix. *Obstet Gynecol*. 1998; 92(5): 737-744.
7. Thai KE, Sinclair RD. Cryosurgery of benign skin lesions. *Australas J Dermatol*. 1999; 40(4): 175-184.
8. Mutalik S. Treatment of keloids and hypertrophic scars. *Indian J Dermatol Venereol Leprol*. 2005; 71(1): 3-8.
9. Meseci E, Kayatas S, Api M, Boza A, Cikman MS. Comparison of the effectiveness of topical silicone gel and corticosteroid cream on the pfannenstiel scar prevention - a randomized controlled trial. *Ginekol Pol*. 2017; 88(11): 591-598.
10. Wong TS, Li JZ, Chen S, Chan JY, Gao W. The Efficacy of Triamcinolone Acetonide in Keloid Treatment: A Systematic Review and Meta-analysis. *Front Med (Lausanne)*. 2016; 3: 71.
11. Lee KL, Zhou Y. Quantitative evaluation of sonophoresis efficiency and its dependence on sonication parameters and particle size. *J Ultrasound Med*. 2015; 34(3): 519-526.
12. Wahba ES, Hamada HA, El Khatib A. Effect of silicone gel versus Contractubex or corticosteroid phonophoresis for post-burn hypertrophic scars: a single-blind randomized controlled trial. *Physiotherapy Quarterly* 2019; 27(1): 1-5.
13. Hamoda RE, Osman DA, Hamada HA, Radwan R, Yousef AM, Abdel Samea GA, Gharib HO. Effect of myofascial release on electro-physiological and clinical measures of pregnant women with carpal tunnel syndrome. *Physiotherapy Quarterly* 2019; 27(1): 18-24.
14. Barara M, Mendiratta V, Chander R. Cryotherapy in treatment of keloids: evaluation of factors affecting treatment outcome. *J Cutan Aesthet Surg*. 2012; 5(3): 185-189.
15. Ahuja, R. B., & Chatterjee, P. (2014). Comparative efficacy of intralesional verapamil hydrochloride and triamcinolone acetonide in hypertrophic scars and keloids. *Burns*, 40(4), 583-588. <https://doi.org/10.1016/j.burns.2013.09.029>
16. Fearmonti R, Bond J, Erdmann D, Levinson H. A review of scar scales and scar measuring devices. *Eplasty*. 2010; 10: e43.
17. Robles DT, Berg D. Abnormal wound healing: keloids. *Clin Dermatol*. 2007; 25(1): 26-32.
18. O'Boyle CP, Shayan-Arani H, Hamada MW. Intralesional cryotherapy for hypertrophic scars and keloids: a review. *Scars Burn Heal*. 2017; 3: 2059513117702162.
19. Rusciani L, Rossi G, Bono R. Use of cryotherapy in the treatment of keloids. *J Dermatol Surg Oncol*. 1993; 19(6): 529-534.
20. van Leeuwen MC, Bulstra AE, Ket JC, Ritt MJ, van Leeuwen PA, Niessen FB. Intralesional Cryotherapy for the Treatment of Keloid Scars: Evaluating Effectiveness. *Plast Reconstr Surg Glob Open*. 2015; 3(6): e437.
21. Baust JG, Gage AA. The molecular basis of cryosurgery. *BJU Int*. 2005; 95(9): 1187-1191.
22. Zouboulis CC. Principles of cutaneous cryosurgery: an update. *Dermatology* 1999; 198(2): 111-117.
23. Dalkowski A, Fimmel S, Beutler C, Zouboulis ChC. Cryotherapy modifies synthetic activity and differentiation of keloidal fibroblasts in vitro. *Exp Dermatol*. 2003; 12(5): 673-681.
24. Zouboulis CC, Zouridaki E, Rosenberger A, Dalkowski A. Current developments and uses of cryosurgery in the treatment of keloids and hypertrophic scars. *Wound Repair Regen*. 2002; 10(2): 98-102.
25. Har-Shai Y, Sabo E, Rohde E, Hyams M, Assaf C, Zouboulis CC. Intralesional cryosurgery enhances the involution of recalcitrant auricular keloids: a new clinical approach supported by experimental studies. *Wound Repair Regen*. 2006; 14(1): 18-2
26. Wu WS, Wang FS, Yang KD, Huang CC, Kuo YR. Dexamethasone induction of keloid regression through effective suppression of VEGF expression and keloid fibroblast proliferation. *J Invest Dermatol*. 2006; 126(6): 1264-1271.